

**ACUTE RHINOSINUSITIS  
DURING UPPER RESPIRATORY  
INFECTION IN CHILDREN**

**AILA  
KRISTO**

Faculty of Medicine,  
Department of Otorhinolaryngology,  
Department of Paediatrics,  
University of Oulu

OULU 2005





*AILA KRISTO*

**ACUTE RHINOSINUSITIS DURING  
UPPER RESPIRATORY INFECTION  
IN CHILDREN**

Academic Dissertation to be presented with the assent of  
the Faculty of Medicine, University of Oulu, for public  
discussion in the Auditorium 7 of Oulu University  
Hospital, on November 18th, 2005, at 12 noon

OULUN YLIOPISTO, OULU 2005

Copyright © 2005  
University of Oulu, 2005

Supervised by  
Professor Olli-Pekka Alho  
Professor Matti Uhari

Reviewed by  
Docent Matti Korppi  
Professor Jouko Suonpää

ISBN 951-42-7871-2 (nid.)  
ISBN 951-42-7872-0 (PDF) <http://herkules.oulu.fi/isbn9514278720/>  
ISSN 0355-3221 <http://herkules.oulu.fi/issn03553221/>

OULU UNIVERSITY PRESS  
OULU 2005

## **Kristo, Aila, Acute rhinosinusitis during upper respiratory infection in children**

Faculty of Medicine, Department of Otorhinolaryngology, Department of Paediatrics, University of Oulu, P.O.Box 5000, FIN-90014 University of Oulu, Finland

2005

Oulu, Finland

### ***Abstract***

Acute rhinosinusitis is estimated to be one of the most common diseases in childhood. Still, the diagnostics and clinical relevance of this disease are controversial.

Bacterial rhinosinusitis cannot be differentiated from mere rhinitis on clinical grounds alone. Abnormal radiologic findings have been found to be common in child and adult volunteers without sinus symptoms and in adults during viral upper respiratory infection. In children, the results of the few placebo-controlled studies on the benefit of antimicrobial treatment of clinically diagnosed acute rhinosinusitis are controversial. Bacteriologic cultures obtained from the middle meatus by rigid nasal endoscopy have been introduced as a way to determine the bacteriology of the maxillary sinus in adults, but they have not been studied in children with acute symptoms.

In this thesis, incidental paranasal abnormalities were found to be common in healthy school children examined by magnetic resonance imaging (MRI). Some of these abnormalities resolved during a follow-up period of 6 months, but new abnormalities appeared in some children. MRI abnormalities of the paranasal sinuses were found to be much more common in children with acute upper respiratory infections, and most of these abnormalities resolve spontaneously. Children with acute rhinosinusitis confirmed clinically and by imaging did not benefit from cefuroxime treatment as compared to placebo. Pathogenic bacteria (*Streptococcus pneumoniae*, *Haemophilus influenzae*, or *Moraxella catarrhalis*) in the nasal middle meatus during acute upper respiratory infection predicted longer duration of the symptoms and signs of common cold.

Based on these findings, imaging methods should not be used in the diagnostics of acute rhinosinusitis in children. Similarly, incidental imaging findings of abnormalities in the paranasal sinuses or in children with symptoms of acute rhinosinusitis are not an indication for antimicrobial treatment. Because middle meatal pathogenic bacteria were found to predict prolonged symptoms of upper respiratory infection, a randomized controlled trial is needed to evaluate the clinical value of middle meatal culture in identifying the children who would benefit from antimicrobial treatment during acute respiratory infection.

**Keywords:** antibiotics, middle meatus, MRI, respiratory infection, respiratory track bacteria, sinusitis, trials



## Acknowledgements

This work was carried out at the Departments of Otorhinolaryngology and Pediatrics, University of Oulu, during the years 1998–2005. The clinical work was carried out at the Departments of Otorhinolaryngology, Pediatrics and Radiology of Oulu University Hospital, and in the health centres of Oulu and Tornio.

I wish to express my sincere gratitude to Professor Martti Sorri, Head of the Department of Otorhinolaryngology, for his encouraging attitude, warm optimism and interest in my scientific work. Professor Juhani Nuutinen and Professor Kalevi Jokinen, former Heads of the Department of Otorhinolaryngology, are acknowledged for creating an inspiring atmosphere for scientific work and for providing the research facilities to carry out this project.

I owe my deepest and warmest gratitude to my supervisor, Professor Olli-Pekka Alho, Department of Otorhinolaryngology, for his competent and warm guidance during my doctoral work. He always had time for numerous discussions of the problems related to the project. His patience, positive attitude and inspiring proficiency have been invaluable.

Equally, I wish to express my special thanks to my other supervisor, Professor Matti Uhari, Department of Pediatrics, for his stimulating attitude to scientific work. His wide knowledge of research and statistics and his interest in my work have been one of the cornerstones of this project.

My sincere gratitude is due to the clinical director of Otorhinolaryngology, docent Jukka Luotonen. He always gave time and attention to my scientific work, but also took care of my clinical career and working facilities. My special thanks are due to the other co-workers from the “respi group”: Terhi Tapiainen, MD, PhD, docent Tero Kontiokari, docent Marjo Renko and Tytti Pokka, BSc, from the Department of Pediatrics, and docent Petri Koivunen and Tiia Kujala, MD, from the Department of Otorhinolaryngology. Our meetings have been joyful, helpful and important during these years. Leevi Luotonen, MD, was one of us until August 2001. I remember him with many thanks as a friendly and helpful co-worker.

I wish to thank docent Eero Ilkko and docent Osmo Tervonen from the Department of Radiology for their interest and careful interpretation of radiographs. Docent Virpi Glumoff from the Department of Microbiology and Professor Maija Leinonen and Tarja

Kaijalainen, MSc, from National Public Health Institute are acknowledged for help and advice in microbiologic examinations.

I am grateful to Professor Jouko Suonpää and docent Matti Korppi for their careful reviews and valuable comments on this thesis. I also thank Mrs. Sirkka-Liisa Leinonen, Lic.Phil., for revising the English language of the original papers and the final manuscript and Mrs. Raili Puhakka for her friendly assistance.

Grateful thanks go to my colleagues in the Department of Otorhinolaryngology: docent Tapio Pirilä, docent Heikki Löppönen, docent Kyösti Laitakari, Heino Karjalainen, MD, PhD, Tuomas Holma, MD, Tomi Penna, MD, Roine Huotari, MD, Mikael Halonen, MD, Jaakko Laitakari, MD, PhD, Antti Raappana, MD, Eeva Löfgren, MD, Samuli Hannula, MD, and the many other colleagues I have had during the years. It has been pleasant to work in a stimulating and friendly atmosphere. Special thanks go to docent Tapio Pirilä for teaching me in the field of nasal surgery.

Thanks to the other staff of the Departments of Otorhinolaryngology, Pediatrics and Radiology in Oulu University Hospital, to the staff of the health centres in Tornio and Oulu, and all the children who participated as study patients.

I am deeply grateful to my close friends Anu Kunnari, MA, Katri Myllyniemi, DDS, Kirsi Mäntyvaara, MA, and Minna Katajala, DDS, who have not always been so interested in my research, but have always been interested in my life and friendship. The discussions and many travels with them and other friends have been invaluable during these years.

Finally, I want to express my warmest thanks to my mother Rauha, who has been optimistic of my career and supported me in my life. My sisters Helena, Marjatta and Seija and brothers Seppo, Tapani and Reima have had a important role in my life, and they have been interested in and supported my work on this thesis. The children of my siblings and their families are my sunshine. My warmest thanks to all of them!

This research project was supported by KEVO funding of Oulu University Hospital, Maud Kuistila Memorial Foundation and Finnish Medical Foundation.

Oulu, October 2005

Aila Kristo

## **List of original papers**

The thesis is based on following reports, which are referred to in the text by Roman numerals.

- I Kristo A, Alho O-P, Luotonen J, Koivunen P, Tervonen O & Uhari M (2003) Cross-sectional survey of paranasal sinus magnetic resonance imaging findings in schoolchildren. *Acta Pædiatrica* 92: 34-36.
- II Kristo A, Uhari M, Luotonen J, Koivunen P, Ilkko E, Tapiainen T & Alho O-P (2003) Paranasal sinus findings in children during respiratory infection evaluated with magnetic resonance imaging. *Pediatrics* 111: e586-e589.
- III Kristo A, Uhari M, Luotonen J, Ilkko E, Koivunen P & Alho O-P (2005) Cefuroxime axetil versus placebo for children with acute respiratory infection and imaging evidence of sinusitis: randomised controlled trial. *Acta Pædiatrica* 94: 1208-1213.
- IV Kristo A, Uhari M, Kontiokari T, Glumoff V, Kajjalainen T, Leinonen M, Luotonen J, Koivunen P, Kujala T, Pokka T & Alho O-P. Nasal middle meatal bacteriology as a predictor of the course of acute respiratory infection in children. *Pediatr Infect Dis J*, in press.

Reproduced with permission from American Academy of Pediatrics and Taylor & Francis Group.



# Contents

Abstract	
Acknowledgements	
List of original papers	
Contents	
1 Introduction .....	11
2 Review of the literature .....	13
2.1 Development and anatomy of paranasal sinuses .....	13
2.2 Physiology of paranasal sinuses .....	14
2.3 Definition of acute rhinosinusitis.....	15
2.4 Pathophysiology of acute rhinosinusitis .....	16
2.5 Microbiology .....	17
2.6 Incidence and risk factors .....	19
2.7 Diagnostics of acute rhinosinusitis .....	20
2.7.1 Symptoms and signs compared to sinus aspiration and culture.....	21
2.7.2 Imaging.....	21
2.7.2.1 Incidental paranasal abnormalities in radiography .....	22
2.7.2.2 Symptoms and signs compared to radiography .....	24
2.7.2.3 Radiography compared to sinus aspiration and culture .....	25
2.7.2.4 Ultrasonography compared to radiography or sinus aspiration .....	25
2.7.3 Nasal and nasopharyngeal cultures.....	28
2.7.3.1 Cultures from the nasal cavity .....	28
2.7.3.2 Cultures from the nasopharynx.....	29
2.7.4 Laboratory tests .....	30
2.7.5 Current recommendations for diagnosing acute rhinosinusitis in children.....	31
3 Purpose of the present study .....	33
4 Patients and methods .....	34
4.1 MRI findings of paranasal sinuses in schoolchildren (I) .....	34
4.2 MRI findings of paranasal sinuses during upper respiratory infection (II).....	35
4.3 Effect of cefuroxime axetil on acute rhinosinusitis (III).....	35
4.4 Nasal middle meatal bacteriology and duration of common cold (IV).....	37

4.5 Statistical analysis.....	38
4.6 Ethical aspects .....	39
5 Results .....	40
5.1 MRI findings of paranasal sinuses in schoolchildren (I) .....	40
5.2 Background characteristics of children in studies II–IV .....	42
5.3 MRI findings of paranasal sinuses during upper respiratory infection (II).....	42
5.4 Resolution of paranasal abnormalities after upper respiratory infection (II) .....	43
5.5 Effect of cefuroxime axetil during acute rhinosinusitis (III) .....	44
5.6 Nasal middle meatal bacteriology and duration of symptoms of common cold (IV).....	46
6 Discussion .....	49
7 Conclusions .....	53
References	

# 1 Introduction

Acute maxillary sinusitis is claimed to be one of the most common diseases in childhood. (1) Children have 6 to 8 upper respiratory infections each year (2,3), and it is estimated that acute bacterial rhinosinusitis complicates up to 13% of these infections. (4,5)

In the past, acute purulent maxillary sinusitis was common and required aggressive treatment and operations. (6,7) In the late 1940's, before the widespread use of antibiotics, beta-hemolytic streptococci and *Streptococcus pneumoniae* were the most common pathogens causative of purulent sinusitis. (8) This situation has changed during last decades (9), however, and the role of viral rhinosinusitis is increasing. Abnormal radiologic findings of the sinuses were earlier recommended to be treated with puncture and aspiration of the maxillary antra (6,10), but according to recent studies in adults, paranasal sinus abnormalities are common even during viral upper respiratory infection (11). Although the recommendation is to diagnose acute bacterial rhinosinusitis only on clinical grounds in young children, bacterial sinusitis cannot be differentiated from rhinitis on clinical grounds alone. (4,12,13) The results of the few placebo-controlled studies on the benefit of antimicrobial treatment of clinically diagnosed acute bacterial rhinosinusitis are controversial. (14,15) The gold standard for the diagnosis of bacterial sinusitis is puncture, aspiration and positive bacteriologic culture of sinuses, which are usually impossible in children without general anaesthesia. Bacteriologic cultures obtained from the middle meatus by rigid nasal endoscopy have been introduced as a way to determine the bacteriology of the maxillary sinus in adults (16), but they have not been studied in children with acute symptoms.

Inappropriate prescribing of antibiotics is common for children with upper respiratory tract infections (17,18) and leads to unnecessary side effects and the emerging phenomenon of antimicrobial resistance (19,20). Accurate diagnostics of acute bacterial rhinosinusitis would help the clinician to find the patients who really benefit from antimicrobial treatment and prevent the complications associated with bacterial sinusitis, such as orbital or intracranial infections. (21–24)

Although the pathophysiology of chronic rhinosinusitis is claimed to begin from the changes of sinuses during acute rhinosinusitis, most studies of rhinosinusitis in children traditionally concern the diagnostics and treatment of chronic disease. In this thesis,

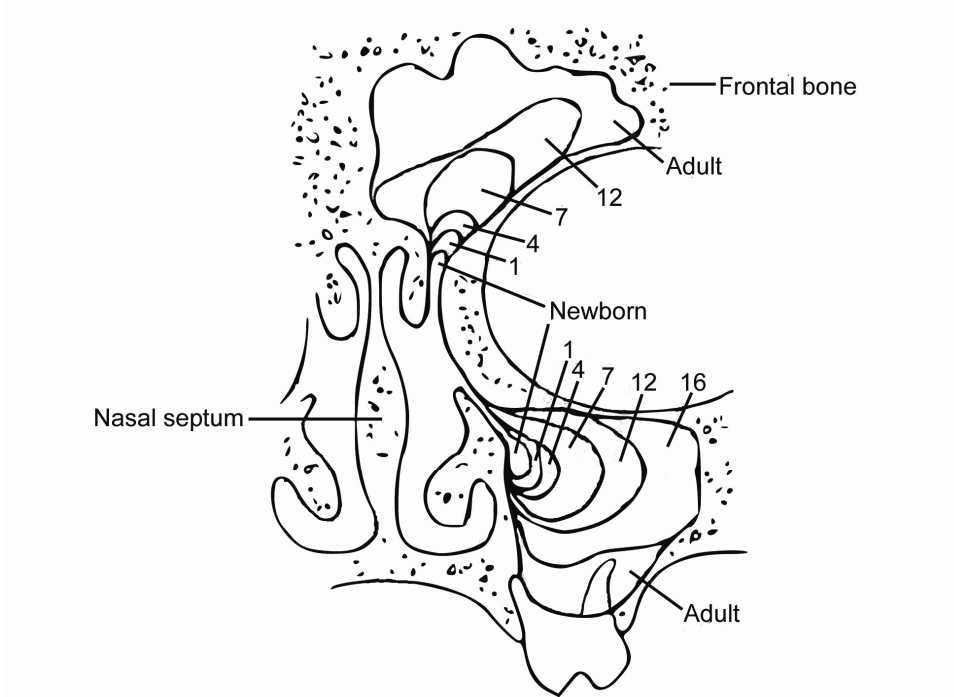
imaging-based and microbiological methods of diagnosing acute rhinosinusitis were evaluated.

## 2 Review of the literature

### 2.1 Development and anatomy of paranasal sinuses

The development of the paranasal sinuses begins very early *in utero*. The maxillary sinus can be seen approximately by day 17 of gestation and it begins as an evagination in the lateral nasal fossa, where the middle meatus develops between the inferior and middle turbinates. (25) By 19 weeks, the cartilaginous wall of the maxillary sinus gradually disappears and the mucosa of the maxillary sinus comes into direct contact with the maxillary bone. (26) The primitive form of the maxillary sinus develops into a maxillary cavity 7–10 mm in length, 4 mm in height and 3–4 mm in width at birth. (25,27,28) In the past, it was assumed that the paranasal cavities are not yet present in young children, who were hence considered unable to develop sinusitis. (29,30) (Fig.1)

The ostiomeatal unit is readily identifiable in CT examination and well developed in early childhood. (31) The ethmoid labyrinth begins to develop at about the third to fifth month of fetal life (25), and the ethmoidal sinus in a newborn can be identified on x-rays (32). By 12–14 weeks, the sphenoid sinus is visible as an invagination of nasal mucosa into the posterior portion of the cartilaginous nasal capsule. (26) The onset of sphenoid pneumatization is observed in 19% of children at the age of 12–15 months, but it usually starts in the third year of life, being complete in children older than 10 years. (28,33) The frontal sinuses develop from anterior ethmoidal cells and move above the orbital ridge by the child's fifth or sixth birthday, showing wide variation in size. (27,28) All paranasal sinuses are completely developed by late adolescence. (27)



**Fig. 1. Development of maxillary and frontal sinuses at different ages. The numbers indicate age in years. (Modified by Graney and Rice (34))**

## 2.2 Physiology of paranasal sinuses

Although the physiological purpose of the paranasal sinuses is unknown, several hypotheses have been published. The possible functions of the paranasal sinuses are phonetic (resonance, sound protection ability for the transmission of one's own speech to the ears), respiratory (reservoir of warm and humid air), olfactory (contributory to the olfactory function in animals, reservoir of air utilized as reference for new olfactory stimuli), static (reduced weight of the facial bones), mechanical (protective against trauma), and thermal (heat insulation of the skull base). (35)

The patency of the ostia, the function of the ciliary apparatus and the quality of secretions are key elements in the normal physiology of the paranasal sinuses. (36) The maxillary, anterior ethmoidal and frontal sinuses drain beneath the middle turbinate in the ostiomeatal area. The ostium of the maxillary sinus is a small tubular structure 2.5 mm in diameter (cross-section about 5 mm) and 6 mm in length, which drains into the ostiomeatal complex. (35) The infundibulum is the drainage pathway of the maxillary sinuses between the uncinat process and the lacrimal bone. Disease in the ostiomeatal complex may produce inflammation that obstructs the infundibulum and drainage.

Ventilation of the sinuses through the ostium must be present. Ciliary activity moves secretions from the sinuses through the ostia and infundibulum into the nasal cavity and further into the nasopharynx. (37) From there, secretions are either swallowed or expectorated. The average velocity of mucociliary transport is about 7.5 mm/min in healthy adults and 8.5 mm/min in healthy children. (38,39) Normal mucociliary function is responsible for the elimination of inhaled particles from the respiratory tract. (40)

### **2.3 Definition of acute rhinosinusitis**

All paranasal sinuses can be infected, but the maxillary and anterior ethmoid sinuses are the most frequent sites of sinus infection. Infection of the maxillary sinuses is most important for a clinician. Isolated involvement of the frontal and sphenoid sinuses is rare. (20)

The term “rhinosinusitis” instead of “sinusitis” is largely accepted since sinus infection is almost always accompanied by concurrent nasal airway inflammation (41), and because most viral infections of the upper respiratory track involve the nose and the paranasal sinuses in adults (11). According to the Clinical Practice Guideline of American Academy of Pediatrics, however, bacterial infections of the paranasal sinuses do not usually involve the nose. (4) The authors presumed that the nose acts as a conduit for secretions produced in the sinuses in patients with bacterial infection of the paranasal sinuses, although data was not provided. Despite the numerous attempts to define “rhinosinusitis”, no consensus has been reached (41), and the definition of acute rhinosinusitis varies according to investigators.

“Rhinosinusitis” is a group of disorders characterized by inflammation of the mucosa of the nose and the paranasal sinuses. (41) The inflammatory process in the sinus mucosa may have a viral, allergic or bacterial origin. (42).

Acute rhinosinusitis is an inflammatory condition involving the paranasal sinuses, as well as the lining of the paranasal passages, and it lasts up to 4 weeks, after which the symptoms resolve completely. Diseases that last for more than three weeks but less than three months are defined as “subacute”, and those that last for more than three months are defined as “chronic”. (41) In some definitions, acute and subacute diseases are regarded as one group, with the symptoms lasting for up to 12 weeks. (43)

Sinus infection is defined as the invasion and multiplication of microorganisms within a sinus. “Viral rhinosinusitis” is, in practice, synonymous to common cold or viral rhinitis. (11,44,45) Most adult patients with viral rhinosinusitis show clinical and radiological recovery without antimicrobials treatment. (11,46,47) For the purposes of research, diagnosis of acute viral rhinosinusitis depends on sinus puncture with the finding of positive virus culture or the detection of viral nucleic acid in cells of the sinus epithelium, indicating viral replication. (41,48) “Bacterial rhinosinusitis” is caused by one or more bacteria present in the sinus in high density (at least 1000 colony-forming units (CFU)/ml). (41)

## 2.4 Pathophysiology of acute rhinosinusitis

Upper respiratory infections are mainly caused by viruses, leading to symptoms of common cold and inflammation of the paranasal sinuses. Viruses causing common cold spread from person to person by virus-contaminated secretions, contact with infected secretions or through inhalation of infected aerosols. (49,50) The pathogenetic mechanisms of various respiratory viruses can be very different from each other. (51) The main binding site for rhinoviruses is ICAM-1 (intercellular adhesion receptor molecule 1) (52), which are mainly located in the area of the nasopharynx (53,54) and the primary site of replication of influenza viruses is the tracheobronchial epithelium (51). Rhinoviruses are frequently present in adenoid tissue in children during the cold months of the year. (55) After intracellular invasion and replication, rhinovirus infection spreads intranasally and into the pharynx. (56) Rhinovirus infections are typically characterized by isolated scattered foci of the infected epithelium between large areas of normal epithelium. (57) After viral replication has started, inflammatory and immune responses are evoked by the host, characterized by vasodilatation, increased vascular permeability, cellular infiltration and release of mediators. (58) Several proinflammatory cytokines, such as IL-1 $\beta$  (interleukine), IL-6, RANTES (Regulated by Activation, Normal T cell Expressed and Secreted), TNF- $\alpha$  (tumor necrosis factor), MPO (myeloperoxidase), ECP (eosinophilic cationic protein), IL-10 and IFN- $\gamma$  (interferon), have been shown to be elevated in nasal lavage, as are also lymphocytes and mast cells in nasal biopsies during common cold. (59,60) Mediators and cytokines results in a cascade of inflammatory reactions, which are responsible for the symptoms of common cold. (58,61)

Paranasal sinus abnormalities have been detected by magnetic resonance imaging (MRI) in adults during experimental rhinovirus infection (46) and by computed tomography (CT) and plain radiography (11,47,62) during community-acquired common cold. It is unknown whether the sinus abnormalities seen during common cold are caused by direct invasion of viruses into the sinus cavity, or whether inflammatory events in the ostiomeatal area are responsible for the development of sinusitis. (63) Rhinovirus RNA has been found inside epithelial cells in biopsies of maxillary sinus mucosa during acute sinusitis, and it is therefore thought that viral replication also occurs in the maxillary sinus epithelium. (63) Thus, radiographic abnormalities during viral rhinosinusitis could be the result of inflammation alone or of viral infection of cells in the sinus epithelium. (41) According to Gwaltney *et al.*, viral rhinitis may lead to sinus disease by obstructing sinus ostium. (11) The sinus epithelium is rich in mucus-producing goblet cells, and it has been thought that part of the material in the sinuses during common cold is the result of goblet cell exocytosis of mucus. (64) On the other hand, in a CT study of adults, nasal blow increased intranasal pressure and contrast medium placed in the pharynx appeared in one or more sinuses, and this may be an important source of the sinus exudates observed during colds. (64,65) Some authors assume that negative pressure following ostial obstruction leads to bacterial invasion into the sinus cavity. (66)

Inflammation is a series of cellular and molecular responses to eliminate foreign agents and to promote the repair of damaged tissue. The inflammatory process of mucous membranes lining the nasal cavity and the paranasal sinuses results in edema and hypersecretion of mucus. (42)

The drainage of secretion from the sinus is dependent on a patent ostium and also on intact mucociliary transport. (35) Common cold results in marked impairment of the nasal mucociliary clearance function, which is due to the loss of cilia and ciliated cells rather than to ultrastructural anomalies in the cilia. In a study of 16 adults with common cold, one week after the onset of symptoms, the loss of cilia and ciliated cells was found to be severe. In samples taken 3 weeks after the beginning of the disease, the amount of cilia and ciliated cells was nearly normal. (67) The transport rate was also markedly reduced in adults with common cold, where the number of ciliated cells decreased, and regeneration was slow. A moderate and short-lasting change in beating frequency and intracellular synchrony was also observed. (68) Impaired mucociliary function has also been found to be common in children with respiratory tract infections, including children with recurrent sinusitis. (69) Nitric oxide (NO) plays an important role in host defence through its potent antiviral properties and is also a regulator of mucociliary function in the nasal airway. (70,71) In an experimental rhinovirus study, six adults were infected with human rhinovirus, and eNO (exhaled nitric oxide) was measured from the nose and lower airways. Significant increases in both eNO concentrations were accompanied by rhinovirus infections. (71) Low nasal NO measurements have been found to be related to low ciliary beat frequency and mucociliary clearance. (72) Very low levels or absence of NO have been found in nasal air sampled from children with Kartagener's syndrome or cystic fibrosis. (70)

Concomitant bacterial infections are common in patients with viral respiratory infection, and some cases of acute viral rhinosinusitis are also complicated by bacterial infection of sinuses. According to a review article by Korppi, dual viral infection is present in 0–14%, dual bacterial infection likewise in 0–14% and mixed viral-bacterial infection in 3–30% of children with pneumonia. (73) In another study, up to 50% of children with respiratory symptoms had a mixed viral and bacterial infection diagnosed by enzyme immunoassay (*Haemophilus influenzae* and *Moraxella (Branhamella) catarrhalis*) or detection of pneumococcal antigens. (74)

## 2.5 Microbiology

The relative proportions of different viruses as causes of common cold and viral rhinosinusitis vary dependent on several factors, such as age, season and the methods of viral sampling and detection. (51) Rhinovirus is the most common cause of common cold in all age groups, accounting for 30–70% of all respiratory illnesses. (2,75–79) Other viruses causing upper respiratory infections are coronaviruses (7–18%), followed by influenza A and B, adenoviruses, parainfluenza viruses, respiratory syncytial viruses (RSV) and enteroviruses, all accounting for minor proportions of common cold. (47,51,76) In the Finnish Otitis Media (FinOM) Cohort Study of children aged from 2 to 24 months, the viral etiology was similar in infection-prone children and children without frequently recurring respiratory infection. (78)

The normal bacteriology of nasal cavities in healthy children differs from that in adults. Major sinus pathogens, such as *Streptococcus pneumoniae*, *H. influenzae* and *M. catarrhalis*, are commonly seen in the nasal cavity in healthy children (80,81), whereas

major sinus pathogens are seen only occasionally in healthy adults. In healthy adults, the most common bacteria are non-pathogenic bacteria, such as coagulase-negative staphylococci, *Staphylococcus aureus*, corynebacteria and *Streptococcus viridans*. (82,83) The virology of nasal cavities or paranasal sinuses has not been studied systematically in healthy children or adults. In experimental common cold studies, rhinovirus infected 95% of the 343 challenged adults, but only 75% of those who became infected developed a cold. The remaining individuals had subclinical infections without symptoms of common cold. (84)

Under normal circumstances, the paranasal sinuses are assumed to be sterile. (4,8,48) On the other hand, Arruda *et al.* found *S. viridans*, *Streptococcus faecalis* and *Staphylococcus epidermidis* from 6 (29%) out of 21 children with normal maxillary sinus radiographs. These children had surgery because of chronic tonsillitis and/or adenoid enlargement, and the finding could thus be due to contamination. (85) Buchem *et al.* made a sinus puncture and culture in children with clinically suspected sinusitis and found that almost 21% (6/29) of radiologically normal sinuses had pathogenic bacteria in maxillary sinus culture. The type of these bacteria was not mentioned, but because *S. aureus* was also regarded as pathogenic, contamination from the nasal cavity could be involved. (13)

Viruses have been detected in the maxillary sinuses during common cold and also during acute bacterial sinusitis in children and in adults (table 1). In a common cold study of adults, viral infection was detected by nasopharyngeal virus culture, antigen detection, serology and rhinovirus PCR (polymerase chain reaction) significantly more often in patients with radiologically confirmed rhinosinusitis than in those without sinus infection (82% (n = 38), and 63% (n = 60), respectively). The most frequent cause was rhinovirus, detected in 55% of the patients with rhinosinusitis and in 48% of those without rhinosinusitis. (47,76) Rhinovirus has also been found to be present in mucosal biopsies of the maxillary sinus. (63)

Studies on the microbiology of acute rhinosinusitis in children have been relatively limited, because maxillary sinus puncture is invasive and requires general anaesthesia. Wald *et al.* conducted two studies in 1979–1982 on children with sinus symptoms for less than 30 days and radiological evidence of maxillary sinusitis (N = 80 altogether, age 1–16 years). At least one maxillary sinus was found to be infected (bacterial growth  $\geq 10^4$  CFU/ml) in 70–77% of children. *S. pneumoniae* was the most common pathogen, followed by *H. influenzae* and *M. catarrhalis*. *H. influenzae* and *S. pneumoniae* are recovered at all ages, whereas *M. catarrhalis* is found more often in younger children. (86,87) Anaerobic bacteria are rarely cultured from the sinuses of children or young adults with acute sinusitis. (87,88) As shown by table 1, where bacterial isolates are listed, the most common bacteria in acute rhinosinusitis are the same as those seen in acute rhinosinusitis in adults.

Because pathogenic bacteria are commonly seen in the nasal cavities and nasopharynx, nasal contaminants are more common in specimens obtained by irrigation. Thus, sinus culture should be taken from puncture and needle aspiration. (89)

Table 1. Microbiological etiology of acute rhinosinusitis in children and adults. Data are from (8,13,44,48,83,86,87,90).

Microbe	Children (%)	Adults (%)
Viruses		
Rhinovirus	1	15–40
Influenza virus		5
Parainfluenza virus	2	3
Adenovirus	2	
Bacteria (range)		
<i>S. pneumoniae</i>	28–36	31 (20–35)
<i>H. influenzae</i>	19–23	21 (6–26)
<i>M. catarrhalis</i>	19	2 (2–10)
Anaerobic bacteria	1	6 (0–10)
<i>S. aureus</i>		4 (0–8)
<i>Str. Pyogenes</i>	1–2	2 (1–3)
Gram-negative bacteria		9 (0–24)
negative	28–35	40

## 2.6 Incidence and risk factors

Maresh and Washburn reported a prospective follow-up study on sinus infections in 1940. They started their study of 100 healthy children in 1925 and made regularly clinical examinations and obtained posteroanterior radiographs of the sinuses four times a year from birth to maturity. They found that the percentage of “pathologic” antrums was 23–35% in children aged 6 to 12 years and 15% in older children. After a recent upper respiratory infection (in previous 2 weeks), less than 50% showed clear sinuses. (91–93)

Viral rhinosinusitis is much more common than bacterial infection of the sinuses. (94) Inflammation of sinus mucosa is common during viral upper respiratory infections in adults. Sinus CT scans obtained in 31 young adults with early common colds revealed abnormalities in the maxillary sinus in 87% of the patients, in the ethmoid sinus in 65%, in the frontal sinus in 32%, and in the sphenoid sinus in 39%. Some of these patients had follow-up CT two weeks later, and most of the changes had resolved spontaneously after resolution of the corresponding upper respiratory track infection. This self-limited process represents viral rhinosinusitis that occurs as part of common cold. (11,94) Viral rhinosinusitis is used in some articles as a synonym for the common cold syndrome. (95) There are no previous studies about sinus findings during common cold in children, but it has been estimated that about 90% of upper respiratory infections show evidence of viral rhinosinusitis. (3,20) Since children have 6–8 viral respiratory infections per year (2,3), viral rhinosinusitis is very common but does not usually require any antimicrobial treatment.

The incidence of acute bacterial maxillary sinusitis varies a lot, because diagnosis is difficult, and viral rhinosinusitis is often misdiagnosed as a bacterial condition. (20) It has been estimated that 0.5–13% of upper respiratory infections are complicated by acute

bacterial rhinosinusitis. (5,66,96) If the duration of respiratory symptoms for more than ten days is used as a diagnostic criterion for acute bacterial rhinosinusitis, 6–13% of children with upper respiratory infections are complicated by acute bacterial rhinosinusitis during the first 3 years of life and 7% at 2 to 15 years of age. (5,96)

The most common factor associated with rhinosinusitis is upper respiratory infection, which is complicated by bacterial infection. (5) Children in day care are about twice more likely to have sinusitis than children in home care. (3,17) Boys are about twice more susceptible to maxillary sinusitis than girls, as they are to recurrent episodes of acute otitis media. (96–98)

Allergy and asthma are commonly associated with sinusitis. (99–103) Allergy may contribute to sinusitis through either nasal congestion and subsequent ostial obstruction or direct allergic effects on sinus-lining cells. (104) The mechanism of association between asthma and paranasal sinusitis has been ascribed to a common allergic mechanism, a nasobronchial reflex, aspiration of sinus secretions, and mediators such as leukotrienes, histamine, and prostaglandin. (105,106) Clinical improvement in the symptoms of asthma has been seen after antimicrobial therapy for sinusitis. (103,107) This may partly be due to the immunomodulatory effects of antimicrobials, which are beneficial for those suffering from asthma. (108–110)

The occurrence of specific immune deficiency in pediatric populations is rare, but some of them are associated with recurrent or chronic sinusitis. (105,111) Congenital abnormalities of the mucociliary clearance mechanism may affect the cilia or the mucus. These conditions are often present with recurrent or chronic sinusitis before the lower respiratory track is involved. (105) Other predisposing factors associated with sinusitis are adenoidal hypertrophy, deviated septum, polyps, foreign bodies, immotile cilia, cystic fibrosis, bronchiectasis, immunodeficiency, barotraumas, dental procedures, tobacco, air pollution, and overuse of topical decongestants. (102,104)

## 2.7 Diagnostics of acute rhinosinusitis

Although sinusitis can be seen in all paranasal sinuses, inflammation or infection of maxillary sinuses is clinically the most important aspect of infection during acute disease. Isolated involvement of the frontal and sphenoidal sinuses is rare (20), although a study in adults showed as high proportion of isolated frontal sinus infection as 19% (112).

Radiologic paranasal sinus abnormalities are common in adults during acute respiratory infection. (11) The majority of these changes consist of mucosal thickening and resolve without treatment during and after the resolution of the symptoms of common cold, and in clinical practice viral rhinosinusitis can be diagnosed without further investigations. In some cases, bacteria from the upper respiratory track cause a complication of bacterial rhinosinusitis.

Bacterial rhinosinusitis should be distinguished from viral upper respiratory infection, and treated with antimicrobials because serious, even life-threatening complications may be associated with this bacterial disease. (21,113–115) The gold (referred) standard for diagnosing acute bacterial sinusitis is the recovery of bacteria ( $\geq 10^4$  CFU/ml) from the paranasal sinus cavity. According to Evans *et al.*, elevated counts of polymorphonuclear

leukocytes in the sinus aspirate are also a useful tool in the diagnosis of acute bacterial rhinosinusitis. (48) These cases require sinus puncture, which is not possible without general anaesthesia in children, and is not recommended as a routine diagnosis for children. (116) Although sinus aspiration with a positive bacterial culture is the only possibility to establish an accurate diagnosis of acute bacterial rhinosinusitis (20), sinus puncture is not recommended in general practice, because the procedure is time-consuming, technically demanding, causes discomfort to the patient and usually requires general anaesthesia in children. According to the Consensus Meeting in Brussels in 1996, the indications for sinus puncture are: severe illness or toxic condition in a child, acute illness in a child that does not improve with medical therapy in 48 to 72 hours, immunocompromised host and the presence of suppurative complications. (12)

The most widely used diagnostic modalities for acute rhinosinusitis are signs and symptoms, radiography and nasal or nasopharyngeal cultures.

### ***2.7.1 Symptoms and signs compared to sinus aspiration and culture***

In the study of Wald *et al.*, symptoms and signs of acute rhinosinusitis were compared between maxillary sinus culture-positive and culture-negative children. There were 30 children, aged 1–16 years, with a history of respiratory symptoms for less than 30 days and radiographically confirmed rhinosinusitis. The presence and duration of headache, dental or facial pain, facial swelling, nasal discharge, malodorous breath, cough and fever were recorded, and all children underwent a physical examination. The patients whose maxillary sinus aspirate cultures were negative could not be distinguished from the patients whose aspirate cultures were positive either on clinical grounds or according to the appearance of the aspirate. No correlation was apparent between the occurrence of specific symptoms and signs and the recovery of a particular bacterial species. (86)

According to some authors, purulent secretion at the middle meatus is a useful finding in the diagnosis of acute bacterial rhinosinusitis (14,117–119), but it is difficult to detect without an endoscope. In the study of Berg and Carefelt concerning 155 adults with sinus symptoms for less than 3 months, purulent secretion from the middle meatus was pathognomic of clinically and radiologically diagnosed bacterial sinusitis. Unfortunately, purulent secretion is a rare finding. The authors of this study only found purulent middle meatal secretion in 9% of their patients with suspected bacterial sinusitis. (118)

A change in the colour (from clear to purulent) and quality (from thin to thick) of nasal discharge may be misinterpreted as a specific indication of bacterial infection, although this sign is part of the natural course of viral respiratory infection. (120–124)

### ***2.7.2 Imaging***

The most common radiographic criteria used for maxillary rhinosinusitis are mucosal thickening of at least 4 mm, total opacification or an air-fluid level. (125) According to some investigators, radiological examination is the most reliable method for diagnosing acute maxillary sinusitis in adults and for differentiating sinusitis from rhinitis. (88,126)

Traditionally, ear, nose and throat surgeons have relied upon a combination of clinical impression and plain sinus radiographs to support the diagnosis of sinusitis. (105)

According to most investigators, occipito-mental projections give enough information in most clinical cases. (93,127,128) On the other hand, in a study of Kuuliala and Revonta, lateral occipito-mental projections were superior in the detection of a fluid level in maxillary sinuses compared to vertical occipito-mental projection in 58 children with symptoms of acute rhinosinusitis. (129) Usually, air-fluid level is an uncommon finding during acute sinusitis in children (14,87,96), but in this study air-fluid level was detected in 15% of sinuses (129).

### 2.7.2.1 *Incidental paranasal abnormalities in radiography*

The value of sinus radiography is controversial, because abnormal radiography findings are common in children without symptoms of sinus disease. This has been documented with plain radiography (85,130–132), CT (93,133–137) and MRI (137–139) as shown in table 2. Two of the studies were made on school children without any medical problem, but the other studies were made unrelated to sinus symptoms, mainly for neurological or ophthalmological reasons.

In some studies, the rate of radiological paranasal abnormalities has been most common among young children (131,133,135), whereas some authors have not found any differences between the age groups (136–138). In the study of Diament, children aged 1–2 years had a higher rate of opacification than children less than 1 year of age. (134) According to some studies, radiological abnormalities are more common in children with symptoms of recent respiratory infection (131,137–139), but some authors have not found any differences (130,133,135,136). Radiological paranasal sinus abnormalities are also common in children with chronic cough without symptoms of sinus infection. (140)

In a series of 33 children with chronic tonsillitis and/or adenoid enlargement without a previous diagnosis of sinusitis, the radiologically most abnormal maxillary sinus was punctured, and aspirates were cultured. Children with complete radiologic opacification of the maxillary sinus had bacterial infection in almost 70% of the cases with symptoms that did not prompt their physicians to consider the diagnosis of sinusitis. (85) These findings were not incidental, since the children had had prolonged symptoms of upper respiratory tract infection, although sinus infection had not been suspected.

Incidental sinus abnormalities in radiography are also common in adults. Some abnormality of the paranasal sinuses was found in 32–53% of the patients with cranial CT or MRI evaluated for reasons other than sinus problems. (141–144) Tarp *et al.* found more abnormalities in adults with nasal symptoms and in the winter season (144), but in the study of Havas *et al.*, the abnormalities were not related to season, age, or the patient's living environment (143).

Table 2. Incidental imaging abnormalities of paranasal sinuses in children

Authors	Imaging method	Age	N	Material	Abnormality of maxillary sinuses (%)	Abnormality of any sinus (%)
Uhari <i>et al.</i> (130)	Plain X-ray	7 and 11 y	55	School children, plain X-ray twice in 4 months	31 and 24	-
Kovatch <i>et al.</i> (131)	Plain X-ray	< 18 y	112	Skull radiographs for reasons unrelated to sinus symptoms	41	-
Haapaniemi (132)	Plain X-ray	6–15 y	663	School children	10–18	-
Glasier <i>et al.</i> (135)	CT	< 1 y	100	Cranial MRI /CT for reasons unrelated to sinus symptoms	64	67
Glasier <i>et al.</i> (133)	CT	1 day–16 y	101	Cranial CT scans without suspected sinus disease	-	31
Diament <i>et al.</i> (134)	CT	< 17 y	137	Cranial CT for neurological of ophthalmological reasons	36	45
Lesserson <i>et al.</i> (136)	CT	< 18 y	142	CT of orbits and temporal bones	39	41
Manning <i>et al.</i> (137)	CT/MRI	1–15 y	60	MRI /CT for reasons unrelated to sinus symptoms	41	55
Gordts <i>et al.</i> (138)	MRI	1 mo–15 y	100	MRI with suspected intracranial neurological disease	29	45
Lim <i>et al.</i> (139)	MRI	< 16 y	60	MRI for reasons unrelated to sinus symptoms	60	38

Delayed resolution of radiographic abnormalities is common in both treated and untreated children and not necessarily an indication of bacterial infection or inadequate treatment. In one study, the relative effectiveness of amoxicillin and amoxicillin-clavulanate potassium was compared to placebo in the treatment of acute maxillary sinusitis in children 2 to 16 years of age. Follow-up radiographic evaluation was available for 59 children who had improved or recovered after ten days of therapy, and the radiographs were unchanged or worse in 22 (37%) cases. Although the children with antimicrobial treatment were clinically cured more often than those in the placebo group, the authors did not mention the follow-up radiographic findings separately in the antimicrobial and placebo groups. (14) The same phenomenon was found in a study of 50 children aged 1–16 years treated with amoxicillin or cefaclor because of clinically diagnosed and radiologically confirmed acute maxillary sinusitis. Of the 100 sinuses studied, 89% had abnormal radiographic findings at the study entry. Follow-up radiographic evaluation was done on 44 patients after approximately 10–14 days. Regardless of clinical improvement, one third of the radiologic findings of the sinuses were unchanged or worse than in the initial radiography. (87) Leopold *et al.* made a prospective MRI study to assess mucosal changes during the resolution of acute maxillary sinusitis. Altogether 13 adults had clinical and MRI examinations up to eight

times after the initiation of amoxicillin-clavulinate treatment. Despite the clinical resolution of symptoms, mucosal changes were seen after more than eight weeks on MRI. (145)

### 2.7.2.2 *Symptoms and signs compared to radiography*

Radiological paranasal sinus abnormalities are very common in children with signs and symptoms of acute rhinosinusitis, as seen in table 3. The variation in the frequency of radiologic abnormalities may be due to differences in the study population, the imaging modality (plain radiography, CT, MRI) and the determination of radiologic abnormality.

Radiological abnormalities in children with suspected rhinosinusitis have been found to be more common in younger age groups than in older children. (14,146) According to the study of Van der Veken, atopy does not affect the frequency of paranasal radiological abnormalities (146), but in another study, children with rhinitis, asthma or immunologic deficiencies had more severe involvement of the paranasal sinuses in radiography. (147) Jannert *et al.* found that the most reliable symptoms and clinical signs of radiologically demonstrable mucosal swelling were purulent nasal secretions on examination, history of upper respiratory infection during the previous two weeks, and sinus pain or tenderness. Altogether 99% of the children with all these symptoms and signs and 75% of those with two of these symptoms and signs had radiological sinus abnormalities. (127)

The severity of symptoms is not related to the degree of sinus abnormality. Wald *et al.* classified 50 children with a history of acute respiratory symptoms as having either 'severe' (n = 20) or 'persistent' (n = 30) symptoms. The children with 'severe' symptoms had been sick for less than 10 days, while the children with 'persistent' symptoms had had persistent symptoms for more than 10 but less than 30 days without improvement. The frequencies of bilateral involvement, air-fluid level, diffuse opacification and mucosal thickening were similar in the children with severe or persistent symptoms. (87) Van Buchem *et al.* found a positive significant correlation between symptoms of cough and purulent discharge with an opaque sinus on radiography in 76 children with clinically suspected sinusitis. The duration of symptoms was not mentioned. (13)

*Table 3. Imaging abnormalities of paranasal sinuses in children with symptoms and signs of rhinosinusitis*

Author	Age	N	Symptoms and signs	Duration of symptoms	Imaging method	Imaging abnormality N (%)
Wald <i>et al.</i> (14)	2–16 y	171	Nasal discharge or daytime cough or both	10–30 days	Plain radiography	131 (80%)
Ueda and Yoto (96)	2–15 y	146	Respiratory symptoms	> 10 days	Plain radiography	135 (93%)
Kogutt and Swischuk (147)	7 mo–14 y	100	Symptoms of suspected sinusitis	Not mentioned	Plain radiography	96 (96%)
Jannert <i>et al.</i> (127)	< 15 y	175	Symptoms of acute sinusitis	“Acute”	Plain radiography	128 (73%)
Barlan <i>et al.</i> (148)	1–15 y	89	Symptoms of acute sinusitis	> 7 days	Plain radiography	79 (89%)
Schwartz <i>et al.</i> (149)*	2.5–12 y	30	Purulent rhinorrhea	1–7 days	Computed tomography (CT)	27 (90%)
Van der Veken <i>et al.</i> (146)	3–14 y	196	Symptoms of suspected sinusitis	Not mentioned	Computed tomography (CT)	125 (64%)

\*CT done after nasal lavage

### *2.7.2.3 Radiography compared to sinus aspiration and culture*

Wald *et al.* compared abnormal radiological findings to sinus culture in children with acute bacterial rhinosinusitis. They found notable bacterial growth in 23 out of 30 children (77%) with clinically and radiologically diagnosed acute rhinosinusitis. (86) Van Buchem *et al.* found radiography to be of doubtful value in the diagnostics of bacterial sinusitis. They obtained radiography and maxillary sinus puncture and culture from children with clinically suspected sinusitis. The duration of symptoms was not mentioned. When *S. pneumoniae*, *H. influenzae*, group A streptococcus, and *S. aureus* were regarded as pathogenic, pathogenic bacteria were found in 40% (25/64) of the sinuses with radiological abnormality (“veiling or mucosal swelling”) and in 21% (6/29) of the clear sinuses. Although exact results were not reported, the authors concluded that ‘the radiographs tend to have more complete opacity in those with pathogenic bacteria, but there was a great overlap’. (13)

### *2.7.2.4 Ultrasonography compared to radiography or sinus aspiration*

The value of ultrasonography as a diagnostic method for acute rhinosinusitis in children is controversial, and there is a large range of research results (table 4). According to some authors, ultrasonography is a simple and reliable screening test for rhinosinusitis in children (150), whereas some others do not support the use of ultrasonography. (13,86,151) As shown in table 4, negative findings of ultrasonography are relatively

reliable (specificity 49–98%), whereas positive findings are less reliable (sensitivity 13–56%). If a positive likelihood ratio  $> 5$  and a negative likelihood ratio  $< 0.5$  are used the markers of useful examination (116), ultrasonography is at least a reasonably useful method for detecting sinus abnormalities. The different results of the reliability of ultrasonography can be explained by different study populations (asymptomatic/symptomatic), differences in examiner training (nurse/radiologist/otorhinolaryngologist) and different definitions of rhinosinusitis.

Some authors have found clinical evaluation alone to be a better way to establish a correct diagnosis of sinus empyema in adults than a combination of clinical evaluation and ultrasonography (specificity 77% and 70%, respectively). (152) In another study, ultrasound was compared to plain radiography in 46 adults with clinical suspicion of sinusitis. The sensitivity of ultrasound was 29–75%, depending on the device used and the degree of opacification on radiography. Overall specificity was 92–94%. (153) According to Blomgren *et al.*, the specificity of ultrasound versus irrigation in the diagnosis of acute maxillary sinusitis in adults was 100% when otorhinolaryngologists or general practitioners made the examination, whereas sensitivity was 29% and 14%, respectively. (154)

Table 4. Concordance of diagnostic findings on ultrasonography and maxillary sinus puncture or radiography

Author	Subjects	Age	N (patients/ sinuses)	Both abnormal/ both normal	Ultrasonography abnormal, reference normal	Ultrasonography normal, reference abnormal	Sensitivity (%)	Specificity (%)	Positive likelihood ratio	Negative likelihood ratio
Reilly <i>et al.</i> (151) <sup>a</sup>	Children with symptoms of sinusitis	2–16 y	53/106 <sup>b</sup> 53/106 <sup>c</sup>	9/57 10/86	8 2	32 8	22 56	87 98	1.7 28	0.9 0.5
Van Buchem <i>et al.</i> (13)	Children with suspected sinusitis	2–12	79/103 <sup>d</sup> 79/124 <sup>a</sup>	2/63 25/33	25 7	13 59	13 30	72 83	0.5 1.7	1.2 0.9
Haapaniemi (132) <sup>a</sup>	Unselected school-aged children	7–14	663/1326	61/1191	27	47	56	98	28	0.4
Haapaniemi and Laurikainen (155) <sup>d</sup>	Adults with acute or prolonged sinusitis	adults	206/290	148/48	50	44	77	49	1.5	0.5
Puhakka <i>et al.</i> (156)	Adults with common cold	adults	200/394 <sup>a</sup> 40/80 <sup>c</sup>	53/261 14/55	39 3	41 8	56 64	87 95	4.3 12.8	0.5 0.4

<sup>a</sup>Ultrasonography compared to plain X-ray. <sup>b</sup>Any abnormality in radiography. <sup>c</sup>Complete opacification in radiography. <sup>d</sup>Ultrasonography compared to sinus irrigation.

<sup>e</sup>Ultrasonography compared to MRI

### 2.7.3 Nasal and nasopharyngeal cultures

The correlation between cultures of nasal cavities and cultures of sinus aspirates during acute rhinosinusitis varies a lot in different studies. (13,48,85) The site of the nasal culture, the use of endoscopic control in the sampling and the patients' age may affect the correlation findings. Most of these studies have been done on adults.

#### 2.7.3.1 Cultures from the nasal cavity

Cultures from the posterior parts of nasal cavities were found to have a good correlation with ipsilateral maxillary sinus aspiration fluid cultures in a study of 185 Finnish adult military service patients with acute maxillary sinusitis, where 267 cultures were compared. When a sinus aspirate culture yielded a presumed sinus pathogen, the same pathogen was found in the nasal samples in 91% of the cases. The predictive value of a pathogen-positive nasal finding was highest for *S. pyogenes* (94%), followed by *H. influenzae* (78%) and *S. pneumoniae* (69%), and lowest for *M. catarrhalis* (20%). (82) A study of Evans *et al.* had 24 adult patients with acute maxillary sinusitis, and they reported a high rate of false-negative nasal cultures and concluded that anterior nasal cultures correlate poorly with direct aspirate cultures. (48)

The role of middle meatal cultures obtained with a rigid endoscope is controversial, and there is no consensus as to whether middle meatal cultures can substitute for sinus punctures in children. (43) According to some authors, endoscopy is recommended as a first-line diagnostic tool for the diagnosis of acute bacterial rhinosinusitis in routine ear, nose and throat practice in adults. (157)

The normal bacteriology of the middle meatus is different in adults and children. Non-pathogenic bacteria, such as coagulase-negative staphylococci, *S. aureus*, *S. viridans* and corynebacteria are the most common bacteria in healthy adults, whereas pathogenic bacteria, such as *S. pneumoniae*, *H. influenzae* and *M. catarrhalis* are only occasionally found in the middle meatus (carriage rates of 0–6% in healthy adults). (158–161) On the other hand, Gordts *et al.* found middle meatal pathogenic bacteria in 70% of 3- to 4-year-old children undergoing other surgical procedures than surgery for ear, nose or throat disease. *S. pneumoniae* was the most frequently cultured organism, followed by *H. influenzae* and *M. catarrhalis*, which were seen in 50%, 40% and 34%, respectively. In the same study, middle meatal culture was taken from 50 children undergoing ear, nose or throat surgery because of adenoid and/or tonsillar hyperplasia, recurrent tonsillitis or recurrent/chronic otitis media. Middle meatal pathogenic bacteria were found in 92% of these children: *H. influenzae* in 68%, *S. pneumoniae* in 60% and *M. catarrhalis* in 50%. The authors did not report the status of the nasal cavities or the sinus findings, and the specimen from the middle meatus was taken using an ear speculum without an endoscope. (80) The authors do not have an explanation for the differences in the middle meatal flora between healthy adults and children. (160)

In some studies, the correlation between the culture samples from the middle meatus and the maxillary sinus have been good in adults with acute and chronic maxillary sinusitis (16,162–164) and also in children with recurrent or chronic sinusitis (165). Examination of the nose and middle meatus with an endoscope can be performed in many children even under local anesthesia. (166–168) Culture specimens from the middle meatus are more likely to be positive than culture from the maxillary antrum. (43,165)

In a study of 39 children with recurrent or chronic sinusitis, cultures were taken during a surgical intervention from 50 middle meatuses, 48 ethmoid sinuses and 23 maxillary sinuses. Endoscopically guided middle meatal samples were obtained after decongestion, local anesthesia with cocaine and nasal endoscopy. Tissue or aspiration cultures of maxillary sinus contents were taken through middle meatal antrostomy or antral irrigation. The agreement between ipsilaterally obtained cultures of the middle meatus and the maxillary sinuses was 83% (19/23) and that between the middle meatus and ethmoid sinuses 80% (33/44). (165) Talbot *et al.* compared the microbiology of the middle meatus to the microbiology of maxillary sinus aspiration in 46 adults with acute sinus symptoms and significant sinus x-ray abnormality. Endoscopy cultures of the pathogenic bacteria *H. influenzae*, *M. catarrhalis* and *S. pneumoniae* demonstrated a sensitivity of 86% and specificity of 91% as compared to the cultures of sinus puncture and aspiration. (16) On the other hand, Axelsson and Brorson compared the bacteriologic findings of middle meatus and maxillary sinus cultures in adult patients with acute maxillary sinusitis and found the same bacteria in only 63% (53/85) of the samples. The same bacteria were found in 81% (548/677) of the ipsilateral middle and inferior meatuses. The swabs were taken with a sterile nasal speculum without an endoscope. (83) Correlations were also studied in 24 rabbits with induced acute sinusitis, and the investigators demonstrated a 100% correlation between middle the meatal and maxillary sinus cultures in those animals. (169)

The role of middle meatal culture as a diagnostic method in children with acute rhinosinusitis is unknown.

### 2.7.3.2 Cultures from the nasopharynx

The agreement between cultures of the nasopharynx and maxillary sinuses has been found to be poor. Wald *et al.* compared the bacteriologic findings from maxillary sinuses to nasopharyngeal culture in 30 children with clinically and radiologically diagnosed maxillary sinusitis. They compared the predominant bacterium recovered from the nasopharyngeal and throat cultures to the sinus aspirates and found no correlation. Although the organism recovered from the sinus aspirate was usually also found in the nasopharyngeal and throat culture, it was rarely the predominant organism. They concluded that nasopharyngeal or throat cultures cannot be used as guidelines for antimicrobial treatment of maxillary sinusitis. (86) The association between nasopharyngeal and maxillary sinus cultures was also low in a study of 39 children with recurrent or chronic sinusitis. The species for culture were obtained at a time of surgery from 27 nasopharynxes, 48 ethmoid sinuses and 23 maxillary sinuses. The same bacteria were found in 45% (9/20) of the nasopharyngeal and maxillary sinus cultures and in 40%

(14/35) of the nasopharynxes and ethmoid sinuses. (165) In another study of 56 adult patients, the same bacteria were detected from nasopharyngeal and maxillary sinus cultures in 43% (16/37) of patients with acute sinusitis and in 16% (3/19) of patients with chronic sinusitis. (9)

In a study of Jannert *et al.* children with pathogenic bacteria in the nasopharynx were found to have more pronounced radiological abnormalities than children without pathogenic bacteria in the nasopharynx. Bacterial culture specimens were taken from the nasopharynx in 103 children with clinical and radiological evidence of acute maxillary sinusitis. Altogether 77% (55/71) of the children with major radiologic findings had pathogenic bacteria in the nasopharynx, compared to 60% (9/15) of those with normal radiography. (127) In the study of Kaiser *et al.*, antimicrobials were found to be effective in adult patients with sinusitis or common cold with *S. pneumoniae*, *H. influenzae* or *M. catarrhalis* in the nasopharynx. (170) A significant association has also been found between nasopharyngeal carriage of *S. pneumoniae* and acute otitis in children (171).

Some authors have observed an increased isolation rate of *H. influenzae*, *S. pneumoniae* or *M. catarrhalis* in the nasopharynx of children with upper respiratory infection (172,173), but some authors have found the frequency of common sinus pathogens in nasopharyngeal culture to be the same in healthy children and children with acute upper respiratory infection (81,174).

#### **2.7.4 Laboratory tests**

Erythrocyte sedimentation rate (ESR), white blood cell count (WBC) and C-reactive protein (CRP) could not give any useful information about the causative agents in 176 young men with acute maxillary sinusitis. The great majority of tests (82%) showed normal values despite pathogen-positive acute maxillary sinusitis. (175) This finding is not in accordance with the result of the study of 174 adults with acute maxillary sinusitis, in which elevated ESR and CRP appeared to be useful diagnostic criteria for acute maxillary sinusitis. The combination of ESR and CRP had a sensitivity of 82% and a specificity of 57% in diagnosing purulent or mucopurulent material in sinus aspiration or lavage (positive likelihood ratio 1.9, negative likelihood ratio 0.32), though microbial etiology was not assessed. (176) In another study, ESR > 10 mm/h was associated independently with acute sinusitis confirmed by CT, whereas WBC or CRP did not have any diagnostic value. (177)

The diagnostic value of laboratory tests has not been studied in children with acute rhinosinusitis, but according to Fireman, WBC and differential and ESR are usually of no clinical value in the diagnostics of acute maxillary sinusitis in children. (119) Also, according to the Finnish guidelines of acute sinusitis, laboratory tests should not be used in the diagnostics of acute rhinosinusitis. (178)

### 2.7.5 *Current recommendations for diagnosing acute rhinosinusitis in children*

The current clinical diagnostic criteria for viral rhinosinusitis include a respiratory infection that is beginning to resolve after a few days and is better by a week to 10 days after onset.

American Academy of Pediatrics recommends that the diagnosis of acute bacterial rhinosinusitis in children six years or younger could be based on clinical criteria only (4), although acute bacterial rhinosinusitis cannot be distinguished from acute viral rhinosinusitis on clinical grounds alone without sinus puncture and culture (12,44). Imaging studies may be necessary to confirm the diagnosis in children older than six years and in all children (regardless of age) with severe symptoms. (4,179) According to a recent review, the greatest predictive value of plain radiography lies in its ability to exclude acute bacterial rhinosinusitis in symptomatic children: normal radiography has a sensitivity of approximately 90% in excluding acute bacterial rhinosinusitis. (180)

Clinical criteria for acute rhinosinusitis in children are divided into severe and non-severe forms (43,104,181):

1. Non-severe acute bacterial rhinosinusitis has symptoms of upper respiratory tract infection that persist without improvement for more than 10 days. Although patients may not be asymptomatic by the tenth day, their condition has virtually always improved.
2. The severe form has unusually severe symptoms of upper respiratory infection with high fever (temperature more than 39°C) and purulent nasal discharge. In this clinical presentation, the duration of symptoms is not important, and antimicrobial treatment is recommended to be started as soon as possible.

These recommendations are mainly based on the studies of Wald *et al.* (14,86,87). Two studies were done partly on the same children with symptoms for less than 30 days and radiologically confirmed sinusitis (age 1–16 years, N = 30 and N = 50). (86,87) Maxillary sinus aspiration and culture were done on one or both sides, and at least one maxillary sinus was found to be infected in 70–77% of children (65–72% of sinuses). The children were treated with amoxicillin or cefaclor, and the clinical cure rates were 81% and 78%, respectively. (86,87) One of the studies of Wald *et al.* was done on 93 children with 10–30 days of nasal discharge, daytime cough or both and radiological maxillary sinusitis. These children were treated with amoxicillin, amoxicillin-clavulanate potassium or placebo. The children treated with an antibiotic were more likely to be cured than those receiving placebo (67%, 64% and 43%, respectively). (14) However, at the follow-up visit, 30–37% of the sinuses in the children with clinical improvement or cure were radiologically unchanged or worse than at enrollment. According to the authors, delayed radiographic resolution is common and does not necessarily indicate inadequate treatment.

In a study of Ueda and Yoto, 2- to 15-year-old children with > 10 days of upper respiratory infection and radiological sinusitis were treated with cefaclor. At follow-up 2 weeks later, 93% of the children were clinically and radiologically cured or improved. Even though this was not a randomised controlled study, the authors assume that the 10-

day mark is a simple and practical diagnostic basis for acute paranasal sinusitis. (96) In contrast, Garbutt *et al.* concluded that the clinical criteria of sinusitis do not provide sufficient evidence. They studied a total of 188 pediatric patients with 10 to 28 days of persistent symptoms and randomised them to receive amoxicillin, amoxicillin-clavulanate or placebo for 14 days. Sinus symptoms were followed by a quantitative symptom score and subjectively by interviewing the parents on telephone. There were no differences between the treatment groups in the improvement rates on day 14 (amoxicillin 79%, amoxicillin-clavulanate 81% and placebo 79%). The authors concluded that clinically diagnosed, uncomplicated acute maxillary sinusitis in children is usually a self-limiting illness of short duration, and that antimicrobials do not offer clinical benefit. (15)

According to the Finnish guidelines, the diagnosis of maxillary sinusitis should be based on symptoms of acute respiratory infection and detection of effusion by ultrasonography or radiography in adults. Rhinosinusitis in children is recommended to be diagnosed mainly on a clinical basis, and repeated radiographies should be avoided. Ultrasonography provides limited information of the quality of mucosal swelling, but it may be useful in the follow-up of secretion, if a child older than seven years suffers recurrent episodes of sinusitis. (178) In the studies of Finnish health centres, ultrasonography and/or radiography were used as a diagnostic method for 80–90% of patients diagnosed with acute maxillary sinusitis (74–79% and 2–5%, respectively). These imaging methods were also used commonly among children (60% of children aged less than five years and 77% of children aged 5–14 years). (182,183)

### **3 Purpose of the present study**

The purpose of the present study was:

1. To evaluate the clinical relevance of the imaging of paranasal sinuses among healthy and sick children.
2. To evaluate the value of antimicrobial treatment in children with radiologically confirmed acute rhinosinusitis.
3. To evaluate the predictive value of nasal middle meatal bacteriology for the course of common cold.

## **4 Patients and methods**

### **4.1 MRI findings of paranasal sinuses in schoolchildren (I)**

All 48 pupils aged 8–9 years (29 boys and 17 girls) in two class groups at one school were informed about the study and asked to participate. Twenty-seven of them volunteered for the first examination in April–May.

The background information and the occurrence of symptoms at the time of examination were inquired from the parents with a questionnaire. The children were examined just before or immediately after the MRI scanning. The children were considered symptomatic if they had a history of recent upper respiratory infection consisting of rhinorrhea or cough, and if nasal discharge and mucosal erythema were observed in the physical examination.

MRI was performed with a 1.5 T MRI scanner (GE Signa, Milwaukee, WI, USA). Axial and coronal T2 (TR 3500, TE 98) and proton density (TR 3500, TE 14) weighted fast-spin echo images were obtained. Contiguous slices 3 mm in thickness ( $23 \times 17$  fov,  $256 \times 224$  matrix) were obtained using a head coil. Mucosal thickening of more than 3 mm, total sinus opacification and an air-fluid level were considered as pathological findings. (138) The more seriously affected side was recorded as the final grade for each sinus. If the sinus was not developed, it was recorded as normal. The volume of the maxillary sinus contents (fluid and mucosa) and the airspace were determined by summing the voxels in the appropriate regions on the contiguous images through the maxillary sinuses, and the percentage volume of opacification in the maxillary sinuses was calculated. (145) The MRI scans were evaluated from hard copies by a radiologist and an oto-rhino-laryngologist. In cases of disagreement, a consensus was reached after re-evaluation.

During the initial visit, each child was asked to participate in a re-examination after 6–7 months, and 18 of them participated.

## **4.2 MRI findings of paranasal sinuses during upper respiratory infection (II)**

The children from 48 day-care centers participated in a trial evaluating the effect of xylitol on the appearance of otitis media during upper respiratory infection. (184) The parents were asked to bring their child to the outpatient clinic of pediatrics, within three days after the onset of symptoms suggestive of respiratory infection (rhinitis, conjunctivitis, cough, ear ache, sore throat and fever). A total of 74 children aged 4 to 7 were offered a possibility to have MRI of paranasal sinuses, and 68 of them were willing to participate. The MRI examination was carried out within the next seven days. Children with acute otitis or tonsillitis requiring antimicrobial treatment, chronic/recurrent sinusitis or prior sinus surgery, claustrophobia or any implanted ferrous material were excluded. After the exclusion of six claustrophobic and two asymptomatic children, altogether 60 symptomatic children (27 boys and 33 girls) were examined.

The occurrence and duration of respiratory symptoms were evaluated. The severity of nasal obstruction, nasal discharge, cough, sneezing, sore throat, headache, chills and fever were graded on a scale from 0 (not present) to 4 (very severe) and summed up to obtain a total symptom score.

MRI was performed with an open resistive 0.23 T MRI scanner (Marconi Medical Systems) with a head surface coil, including axial and coronal T2-weighted (TR 4300 ms, TE 126 ms) fast-spin echo images with a 4-mm slice thickness, a 210-mm field-of-view, and a 256 × 256 acquisition matrix. The gradings of the paranasal sinuses were: grade 0: ≤ 2 mm mucosal thickening, grade 1: over 2 mm mucosal thickening - 1/3 volume loss, grade 2: 1/3 - 2/3 volume loss and grade 3: more than 2/3 volume loss or air-fluid level. The final grade for each sinus was determined from the more severely affected side, and the grades was summed up to obtain a total MRI score (range 0–24 for all paranasal sinuses). Grade 0 and undeveloped sinuses were recorded as a normal finding, grade 1 as minor abnormality, and the grades 2–3 as major abnormality.

In case of major abnormality in the maxillary sinus on the initial MRI scan, the child was offered the possibility of a follow-up scan two weeks later. The symptoms, medications and acute complications between the two scans were recorded.

## **4.3 Effect of cefuroxime axetil on acute rhinosinusitis (III)**

We selected the participants at one primary health centre in Oulu from among all children aged 4–10 years who presented with acute respiratory complaints. The study was conducted between November 1998 and March 1999 and between October 2000 and March 2001. To be eligible, the child had to have acute respiratory symptoms suggestive of sinusitis that were not improving and an abnormal ultrasound finding of at least one maxillary sinus. The exclusion criteria were: respiratory symptoms for more than 3 weeks, antimicrobial treatment within 4 weeks of screening, ongoing antimicrobial treatment, allergy to cephalosporin, complications of sinus disease and a prior sinus operation.

The parents recorded the presence and duration of eight acute symptoms: severity of nasal obstruction, nasal discharge (clear or coloured), day- or nighttime cough, sneezing, sore throat, headache, chills and fever. The symptoms were graded on a scale from 0 (not present) to 4 (very severe) and summed up for a total symptom score. (185)

The same otolaryngologist carried out the clinical examination and the ultrasonography of the maxillary sinuses. Ultrasonography was done using a portable Sinuscan 101 (Oriola, Helsinki, Finland) with a frequency of 3 MHz and a transducer diameter of 8 mm in an upright position, as described previously. (186) Three or more echoes reflected in the probe were considered as either mucosal thickening (distance to the third echo < 2cm) or fluid ( $\geq 2$  cm). A finding of at least 5-mm mucosal thickening or fluid in at least one maxillary sinus was considered abnormal.

The plain radiographies (occipitontal view) taken on day 1 were interpreted at the end of the study by an otolaryngologist and a radiologist, who were blinded to the clinical course and the results of ultrasonography. A radiological diagnosis of sinusitis was made if mucosal thickening of at least 4 mm, an air-fluid level or total opacification in at least one maxillary sinus was detected. Specimens for aerobic bacterial cultures were taken from the nasopharynx. The swabs were inoculated on blood and chocolate agar plates according to routine procedures.

Each patient received either cefuroxime axetil in 125-mg capsules twice a day for 10 days or placebo in a similar form at a similar frequency. The use of analgesics, nose drops and cough mixtures was allowed, the amount being recorded in the diary.

The parents were instructed to keep a diary of the presence of six symptoms (fever, cough, nasal discharge, nasal obstruction, headache and otalgia) and the administration of the study and other medication. Follow-up visits were scheduled on day 14, and based on the symptoms and signs assessed by one clinician and by the parents, the child's condition was classified as cured, improving, unchanged or deteriorated. Plain radiography and bacterial specimens were repeated, and symptom diaries and residual drugs were collected.

Any child whose symptoms were aggravated during the follow-up was re-examined. In case the disease had progressed, which was defined as persistent fever  $\geq 38^{\circ}\text{C}$  for three consecutive days and/or severe fatigue, or otitis media or pneumonia was diagnosed, the child was defined to have a complication, and the code was opened. Placebo was replaced by amoxicillin (40 mg/kg/day), and cefuroxime was continued as planned.

The primary outcome measure was the percentage of children with complete cure in 2 weeks as assessed by the clinician and the parents. The other end points were the percentage of children with improvement without complications, the percentage with side effects and the mean difference in symptoms and days when analgesics, nasal decongestants or cough mixtures were given.

#### 4.4 Nasal middle meatal bacteriology and duration of common cold (IV)

The parents of about 3700 school children in the towns of Oulu and Tornio were informed about the study by a letter. An advertisement about the study was published once in a local newspaper.

If a child had any symptoms suggestive of respiratory infection, the parents were asked to bring him/her to the clinic within 10 days of the beginning of the episode. The child was eligible if he/she had had symptoms of respiratory infection, including rhinorrhea and/or cough. Children with infection requiring antimicrobial treatment or with upper respiratory infection or antimicrobial treatment within 4 weeks preceding the screening visit were excluded. Children with diabetes, immunological deficiency or facial anomalies were also excluded. The parents completed a questionnaire of the presence and duration of nasal obstruction, nasal secretion (clear/colored), cough, headache, sore throat and fever at enrolment. Each symptom was graded on a scale from 0 (not present) to 3 (very severe) and summed up to obtain the total symptom score. An ear, nose and throat examination was done on all children.

The parents were instructed to keep a diary of the presence of four symptoms (nasal discharge (clear/coloured), nasal obstruction and cough). The use of analgesics, antihistamines, nasal corticosteroids and nose drops was allowed, the amount being recorded in the diary. Any child whose symptoms were aggravated during the follow-up was re-examined. Antimicrobials were used if needed, i.e. if the disease progressed or the child developed complications. At a follow-up visit three weeks later, the diaries were collected and the child was re-examined.

One hundred children volunteered to participate, but 18 of them were excluded (7 had had symptoms for more than 10 days, 5 had otitis media, 3 had had respiratory infection within four weeks preceding the screening visit, 2 were of unsuitable age and one had a sore throat without nasal symptoms or cough). Thus, 82 children (42 boys, mean age 9.8 years, range 6–13) entered the study, of whom 80 attended the follow-up visit.

At enrolment, specimens for virologic analysis were taken by aspirating nasal secretion with a glass suction tip under visual control with a headlamp and a nasal speculum, about 10 mm inside the nostril from the bottom of the nasal cavity. Secretion was diluted with 1.5 ml of normal saline and stored frozen at -70°C. Total nucleic acids were purified from 250 µl of nasal sample, using the High PureViral Nucleic Acid Isolation Kit (Roche Applied Science, Germany). Nucleic acid isolation was carried out as recommended by the manufacturer, except that the nucleic acid elution buffer was pre-warmed to 72°C before adding it into the column. The column was incubated at 72°C for 1 min prior to final centrifugation. Parainfluenza, Influenza and RSV viruses were detected by the Prodesse Hexaplex® Plus Kit (Prodesse, Waukesha, WI, USA). Enteroviruses and rhinoviruses were detected according to the method of Lönnrot *et al.* (187). Instead of lanthanide chelate-labelled probes, DIG-labelled probes were used. For adenovirus detection, an in-house test was developed according to Gröndahl *et al.* (188)

At enrolment and at follow-up, bacteriologic samples were taken as follows. Secretion from the middle meatus on both sides was obtained with a cotton swab under the control of a 2.7-mm thick 30° rigid endoscope. The children were informed about the sampling,

which was done without decongestant or topical anesthesia, avoiding contamination of the skin of the nares. Specimens for aerobic bacterial cultures were taken from the nasopharynx through the mouth using an angled cotton swab. The samples were immersed in a tube containing 1 ml of STGG (skim milk, tryptone, glucose, glycerol) medium and stored frozen at  $-75^{\circ}\text{C}$ . (189) The nasopharyngeal specimens were cultured on 5% sheep blood agar (Trypticase Soy agar BBL 11043, Muller Hinton agar BBL 11438, USA) and sheep blood agar with gentamicin ( $5\ \mu\text{g/ml}$ ) plates. The middle meatal specimens were cultured on blood agar and enriched chocolate agar plates. The plates were incubated in 5%  $\text{CO}_2$  at  $+37^{\circ}\text{C}$  for 18 to 24 h. Colonies suspected as *S. pneumoniae* from nasopharyngeal specimens and *S. pneumoniae*, *H. influenzae* and *M. catarrhalis* from middle meatal specimens were identified using generally accepted methods as described earlier. (190) The number of bacterial colonies as well as the amount of normal flora were recorded.

*S. pneumoniae*, *H. influenzae* and *M. catarrhalis* were considered as potentially pathogenic bacteria in the middle meatus. The only pathogenic bacterium identified from the nasopharynx was *S. pneumoniae*.

The primary outcome measure was the mean duration of the symptoms of acute respiratory infection. The numbers of symptomatic days before and after enrolment were summed up, the latter being taken from the diary. After three asymptomatic days, the episode was considered to be cured.

#### 4.5 Statistical analysis

Summary statistics are expressed as means, medians and standard deviations (SD) for descriptive purposes. Fisher's exact test, Mann-Whitney U-test,  $\chi^2$ -test and SND test were used to analyze the interdependencies between two variables for unpaired data (studies II–IV) and Kruskal-Wallis analysis of variance with more groups (study II). Wilcoxon's ranked-pairs analysis was used for analysing paired data, and correlation coefficients were calculated using Spearman's rank correlation (study II). In the placebo-controlled study (III), the data were analysed on the per protocol basis. The differences in means with 95% confidence intervals were calculated to compare the proportions of children with complete cure and with improvement without complications in the groups receiving cefuroxime or placebo (study III) and to compare the numbers of symptomatic days in the children with and without middle meatal pathogenic bacteria (study IV). (191) The times to complete elimination of symptoms relative to the findings of middle meatal pathogens were analysed by means of Kaplan-Meier curves, and the differences between the groups were tested with the log rank test. (192,193) The Cox proportional-hazards regression model was used for multivariate analysis. (194) The cumulative risk of failure to cure was calculated as a hazard ratio with 95 percent confidence intervals, which were adjusted for age, sex, allergic rhinitis and viral findings (positive/negative) (study IV).

## **4.6 Ethical aspects**

All the studies were approved by the ethics committee of Oulu University Hospital. Informed consent was obtained from the parents in all cases and also from the child whenever appropriate. MRI and ultrasonography examinations are safe, painless and non-invasive without exposure to ionising radiation. Plain radiography causes ionising radiation, which was minimised by obtaining an X-ray image in only one direction. Bacterial sampling of the middle meatus causes discomfort and requires good co-operation of the child, but the sampling is otherwise non-invasive.

## 5 Results

### 5.1 MRI findings of paranasal sinuses in schoolchildren (I)

The final series consisted of 24 children, mean age 8.9 years (ranging from 8.4 to 9.7 years). Nineteen of them were asymptomatic and 5 were symptomatic in terms of their history and the clinical examination.

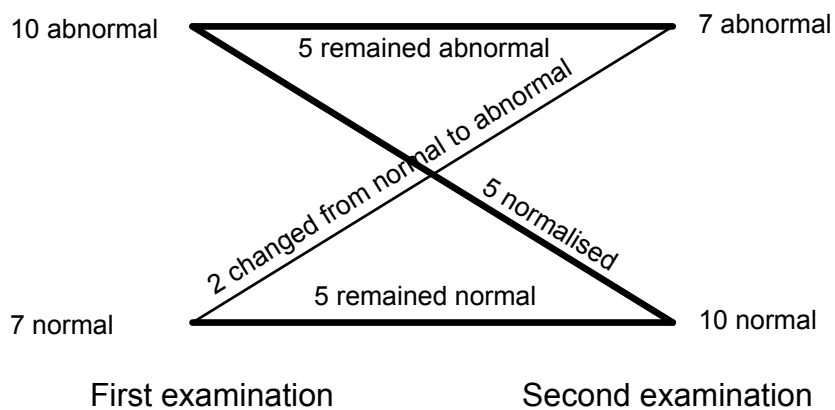
Some form of sinus abnormality was found in 12 children (50%, 95% CI 29–71%). Changes in the ethmoidal sinuses were found in 10 (42%, 95% CI 22–63%) and abnormalities in the maxillary sinuses in nine (38%, 95% CI 19–59%). Sphenoidal abnormalities were found in 3 cases (13%, 95% CI 3–32%) and frontal sinus abnormalities in 3 (13%, 95% CI 3–32%). Ten of the children (42%) had undeveloped frontal sinuses, and one had undeveloped sphenoidal sinuses. The asymptomatic children had sinus abnormalities in their MRI in 8/19 cases (42%, 95% CI 20–67%) (Table 5). The mean percentage opacification in the volume of the maxillary sinuses was 18% among the symptomatic children and 11% and among the asymptomatic children.

Eighteen of the children attended the follow-up examination after six months. One child was excluded because the scan was technically inadequate due to a dental bridge. Abnormal MRI findings were seen in seven children on this occasion (41%, 95% CI 18–67%), the most frequent abnormality being mucosal thickening of the ethmoids (41%, 95% CI 17–64%). Five of the 13 asymptomatic children had abnormal MRI findings (38%, 95% CI 14–68%). The previous abnormalities of the maxillary sinus had resolved without any treatment in 63% of the cases (95% CI 25–92%) and those concerning the ethmoidal sinus findings in 42% (95% CI 15–72%) (Fig. 2).

*Table 5. Prevalence of current nasal symptoms and signs versus MRI findings in the first examination (n = 24)*

MRI findings	Asymptomatic (n = 19)	Symptomatic* (n = 5)	Total (n = 24)
Maxillary sinuses			
Normal	14	1	15
Abnormal	5	4	9
Ethmoidal sinuses			
Normal	13	1	14
Abnormal	6	4	10
Any sinus			
Normal	11	1	12
Abnormal	8	4	12

\*Children were considered symptomatic if they had a history of recent upper respiratory infection consisting of rhinorrhea or cough, and if nasal discharge with mucosal erythema was observed in the physical examination



**Fig. 2. MRI findings of paranasal sinuses in children who participated in two examinations at six-month interval (n = 17).**

## 5.2 Background characteristics of children in studies II–IV

Altogether 214 children aged 3.9–13.2 years attended the studies II–IV. Ninety-nine of them were seeking medical help because of upper respiratory infection; 115 attended only as study subjects. Other details of the baseline characteristics are shown in table 6.

*Table 6. Baseline characteristics of the 214 children with symptoms of upper respiratory infection attending the studies II–IV.*

Characteristics	Patients seeking medical help N = 99	Patients not seeking medical help N = 115
Mean age in years (SD)	8.0 (2.3)	7.6 (2.4)
Female, no (%)	49 (50)	56 (49)
Allergic rhinitis, no (%)	7 (7)	18 (16)
Asthma bronchiale, no (%)	2 (2)	10 (9)
Recurrent otitis media, no (%)	12 (12)	18 (16)
Recurrent treatment for rhinosinusitis, no (%)	11 (11)	2 (2)
Adenoidectomy, no (%)	38 (38)	42 (37)
Tonsillectomy, no (%)	6 (6)	5 (4)
Symptoms		
Mean duration of symptoms (SD)	7.3 (5.1)	5.7 (3.4)
Nasal symptoms (%)	98 (99)	110 (96)
Clear discharge (%)	77 (78)	79 (69)
Coloured discharge (%)	58 (59)	57 (50)
Nasal obstruction (%)	93 (94)	96 (84)
Cough (%)	92 (93)	90 (78)
Headache (%)	65 (66)	36 (31)
Sore throat (%)	65 (66)	54 (47)
Fever (%)	53 (54)	24 (21)
Radiologic maxillary sinusitis <sup>a</sup>	59 (82)	37 (63)

<sup>a</sup>Radiography of the sinuses done on 132 of the children

## 5.3 MRI findings of paranasal sinuses during upper respiratory infection (II)

The subjects had had symptoms of an uncomplicated acute respiratory infection for an average of six days (mean 6.5 days (SD 3.0) range 2–12), and the mean overall symptom score was 6.5 (SD 4.0).

Altogether 68% of the children had major abnormalities in their paranasal sinuses (Table 7). The opacity of these abnormal findings indicated in most cases the density of mucosal swelling.

The mean MRI scores correlated significantly with the symptoms scores ( $r_s = 0.3$ ,  $p = 0.02$ ), but not with the duration of symptoms ( $r_s = -0.04$ ,  $p = 0.73$ ). Of the individual symptoms, nasal obstruction, nasal discharge and fever were significantly related to the MRI scores.

*Table 7. Findings in magnetic resonance imaging during acute respiratory infection in a series of 60 children*

Sinus	Normal	Minor abnormality	Major abnormality	Mean score (SD)
	N (%)	N (%)	N (%)	
Maxillary	15 (25)	9 (15)	36 (60)	1.8 (1.2)
Ethmoidal	10 (17)	13 (22)	37 (62)	1.9 (1.1)
Frontal	16 (27)	6 (10)	11 (18)	1.1 (1.2)
Sphenoidal	31 (55)	6 (10)	20 (35)	1.1 (1.3)
All	7 (12)	12 (20)	41 (68)	8.5 (6.8)

Normal = less than 2-mm mucosal thickening; Minor abnormality = less than 1/3 volume loss; Major abnormality = more than 1/3 volume loss or an air-fluid level. The final grade was determined according to the more severely affected side. \*Frontal sinuses were not developed in 24 children and not displayed in the slices in 3 children. †Sphenoidal sinuses were not developed in 3 children. ‡Calculated for all the sinuses on both sides.

#### **5.4 Resolution of paranasal abnormalities after upper respiratory infection (II)**

Of the 26 children attending the follow-up examination, 9 (35%) had fully recovered from the respiratory infection, 9 (35%) continued to have symptoms, and 8 (30%) had developed a new respiratory infection. Two children had received antimicrobial treatment.

Overall, the MRI findings had improved significantly from the initial scans ( $p = 0.001$ ). Despite the improvement, however, 69% of the 26 most severely affected children still had major abnormalities in their sinuses (Table 8). The MRI scores at the control visit did not correlate significantly with the control visit's symptom score ( $r_s = 0.21$ ,  $p = 0.29$ ) or the MRI scores at the initial visit ( $r_s = 0.09$ ,  $p = 0.66$ )

*Table 8. Findings in magnetic resonance imaging during an acute respiratory infection and at a follow-up visit two weeks later in a series of 26 children with major abnormal findings in the first scan*

Sinus	Acute visit				Follow-up visit			
	Normal	Abnormality		Mean score (SD)	Normal	Abnormality		Mean score (SD)
	N (%)	Minor N (%)	Major N (%)		N (%)	Minor N (%)	Major N (%)	
Maxillary	-	-	26 (100)	2.7 (0.4)	10 (38)	7 (27)	9 (35)	1.3 (1.3)
Ethmoidal	-	3 (12)	23 (89)	2.5 (0.7)	8 (31)	6 (23)	12 (46)	1.3 (1.1)
Frontal*	3 (21)	4 (29)	7 (50)	1.7 (1.2)	12 (75)	1 (6)	3 (19)	0.6 (1.1)
Sphenoidal**	8 (35)	2 (8)	13 (55)	1.7 (1.4)	15 (60)	4 (16)	6 (24)	0.8 (1.1)
All				12.7 (5.6)***				5.7 (5.2)***

Normal = less than 2 mm mucosal thickening; Minor abnormality = less than 1/3 volume loss; Major abnormality more than 1/3 volume loss or air-fluid level. The final grade was determined according to the more affected side. \*Frontal sinuses were not developed in 10 children and not displayed in the slices at the acute visit in 2 children. \*\*Sphenoidal sinuses were not developed in 1 child and not displayed in the slices at the acute visit in 2 children. \*\*\*Calculated for all the sinuses on both sides.

### 5.5 Effect of cefuroxime axetil during acute rhinosinusitis (III)

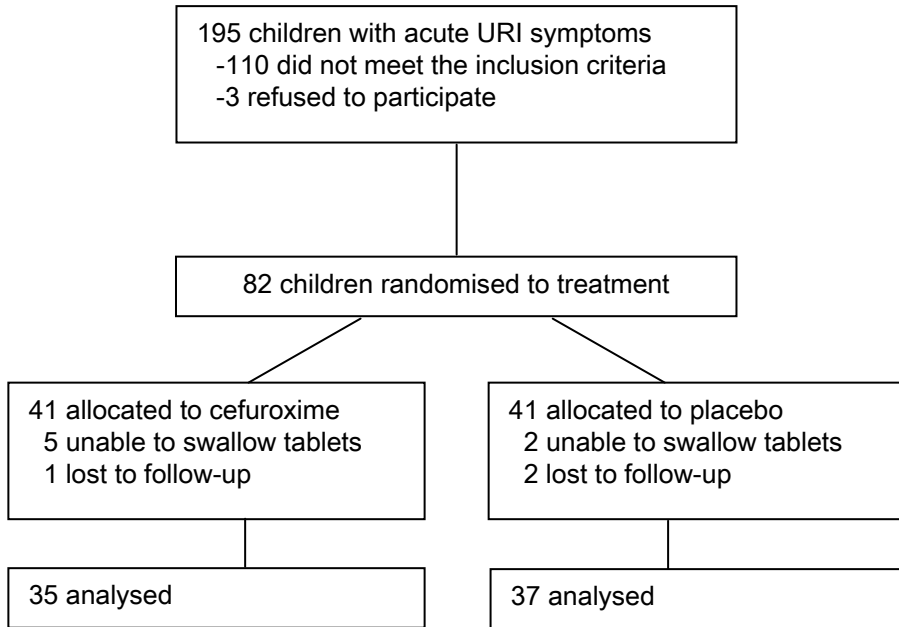
Altogether 82 children were randomly allocated to one of the treatment groups (Fig. 3). Inability to swallow the tablets and loss to follow-up reduced the number of children analysed to 72 (88%). The baseline characteristics were similar between the cefuroxime and placebo groups. Overall, 65 out of the 72 (90%) had severe ( $\geq 4$ mm) mucosal oedema, an air-fluid level or total opacification in either maxillary sinus in the plain radiograph on day 1. The children had had symptoms for an average of 8.4 days (SD 5.6), and there were no significant differences between the groups or in the severity and quality of acute respiratory symptoms.

By day 14, altogether 43 children (60%) had cured completely, 20 (28%) had improved, 4 (6%) had remained the same, and 5 (7%) had developed a complication (2 children from the cefuroxime group, and 3 children from the placebo group).

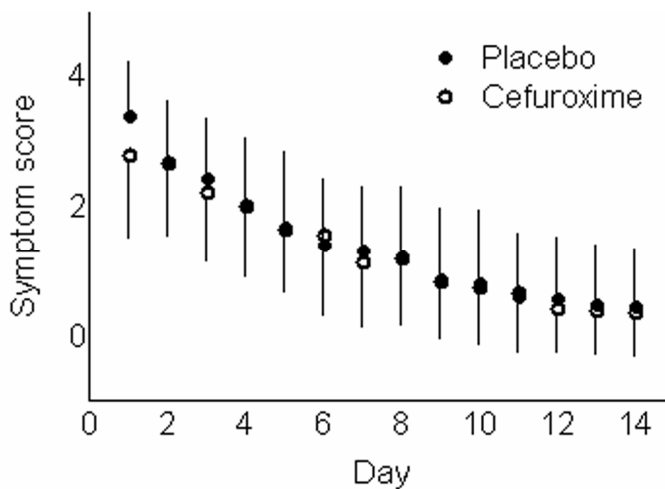
The number of children who had cured completely in 2 weeks was 22 out of 35 (63%) in the cefuroxime group and 21 out of 37 (57%) in the placebo group. Similarly, there were no significant differences between the groups in the percentages of children who had improved without complications (Table 9). These proportions remained similar in the two groups among children aged under and over 6 years of age. The disappearance of symptoms was comparable between the groups as well (Fig. 4).

No significant differences were observed between the two groups in the numbers of days when analgesics, nose drops or cough mixtures were given. By day 14, the proportions of children with findings of radiological sinusitis were similar in the cefuroxime and placebo groups (69% vs. 64%, respectively). The radiological findings at day 14 did not correlate with any of the outcomes (data not shown).

One child in the cefuroxime group and two children in the placebo group were reported to have diarrhoea as an adverse effect. The mean numbers of forgotten doses in the cefuroxime and placebo groups during the trial were 0.5 and 0.3, respectively.



**Fig. 3.** Trial profile and participant flow of study IV



**Fig. 4.** Mean (SD) symptom scores in children with acute rhinosinusitis according to treatment assignment (35 children in placebo group and 37 children in the cefuroxime group)

Table 9. Primary outcome measures at day 14 in children with acute rhinosinusitis according to treatment assignment.

Measure	Cefuroxime (n = 35)	Placebo (n = 37)	Difference in % (95% CI)	P*
All children				
No (%) with complete cure	22/35 (63)	21/37 (57)	6 (-16 to 28)	0.64
No (%) with improvement without complications**	32/35 (91)	31/37 (84)	7 (-9 to 24)	0.48
Children ≤ 6 years of age				
No (%) with complete cure	6/10 (60)	9/17 (53)	7 (-31 to 42)	1.0
No (%) with improvement without complications**	9/10 (90)	13/17 (77)	13 (-21 to 41)	0.62
Children > 6 years of age				
No (%) with complete cure	16/25 (64)	12/20 (60)	4 (-24 to 32)	1.0
No (%) with improvement without complications**	23/25 (92)	18/20 (90)	2 (-17 to 24)	1.0

\*Fisher's exact test. \*\*Defined as otitis media, pneumonia, severe clinical orientation (persistent fever  $\geq 38^{\circ}\text{C}$  for three consecutive days and/or severe fatigue).

## 5.6 Nasal middle meatal bacteriology and duration of symptoms of common cold (IV)

At enrolment, the children had had symptoms for an average of four days (range 1–10). The parents of twenty-seven (33%) children reported that they would have sought medical attention regardless of the study. The endoscopic procedure and the bacteriologic sampling succeeded in all children. Viral etiology was verified in 39 (54%) out of the 72 children analysed. Thirty-eight children (46%) had at least one pathogenic bacterium in their middle meatus. The children without nasal pathogens tended to be older and allergic and to have proven viral infection more often than the children with pathogens.

Of the 80 children who returned their symptom diaries, 63 (79%) had fully recovered from their initial respiratory infection, 5 (6%) had developed a new respiratory infection, and 12 (15%) continued to have symptoms. Follow-up endoscopic sampling was done on 80 children (98%). One child declined the second sampling because he had found the first sampling uncomfortable. No adverse events were related to the endoscopy or the sampling. Five children had received antimicrobial treatment before the follow-up visit because of progressing symptoms. Forty-three children (54%) had used analgesics or nose drops during the follow-up, but there were no significant differences in the mean number of days when these medicines had been used between the children with and without nasal pathogens at entry ( $P = 0.66$ ).

Among the 38 children with nasal bacteria present at entry, 13 had *H. influenzae*, 12 had *S. pneumoniae*, 7 had *M. catarrhalis* and 6 had combinations of these bacteria. Seventeen (45%) of these children no longer had pathogenic bacteria at the follow-up visit, whereas in two new children a pathogenic bacterium had emerged. *S. pneumoniae*

was isolated more commonly from the nasopharynx than from the middle meatus (31/82, 38%, vs. 17/82, 21%). Of the 17 children with *S. pneumoniae* in the middle meatus, 12 (71%) also had the pathogen in the nasopharynx.

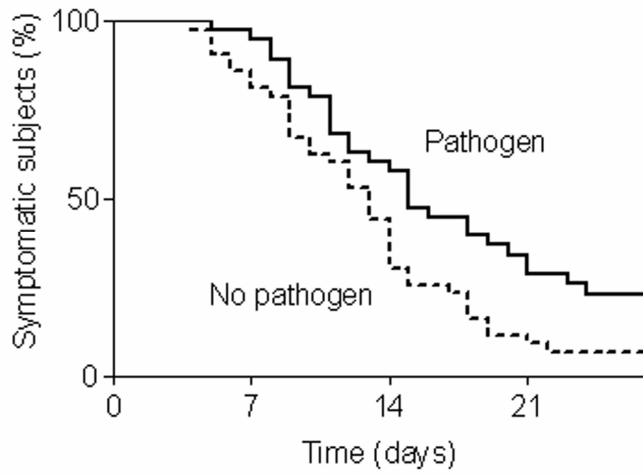
The children with nasal middle meatal pathogens at entry had a significantly longer mean duration of symptoms than the children with non-pathogenic bacteria (Table 10). The children with more than one pathogen had symptoms for a longer time, but otherwise there were no significant differences between the different pathogens. The time to recovery was significantly longer in the children with middle meatal pathogens at entry compared to the children without them ( $P = 0.014$ , log rank test) (Fig. 5). The effect of pathogenic bacteria was significant (unadjusted hazard ratio, HR, for prolonged recovery 1.68, 95% CI 1.1–2.6) and remained significant after adjustment for age, sex, allergic symptoms and the presence of virus (adjusted HR 2.0, 95% CI 1.1–3.6). The children with *M. catarrhalis* had longer cough episodes than those without ( $P = 0.003$ ), but no other significant associations between the bacteria and symptoms were seen.

Table 10. Effect of prognostic factors on the duration (days) of acute respiratory infection in children\*

Prognostic factor	Factor present		Factor absent		Difference in mean (95% confidence interval)	P**
	No.	Mean (SD) duration of symptoms	No.	Mean (SD) duration of symptoms		
Middle meatal bacteria (yes vs no)***	38	16.7 (7.0)	42	13.1 (6.0)	3.6 (0.7–6.5)	0.025
Middle meatal bacteria (multiple vs no)***	6	20.0 (6.7)	42	13.1 (6.0)	6.9 (1.5–12.2)	0.023
No proven viral infection (yes vs no)	32	16.3 (7.6)	38	13.3 (5.3)	3.0 (-0.1–6.0)	0.148
Young age (7–9 yr vs 10–13 yr)	35	14.7 (6.8)	45	14.9 (6.7)	-0.2 (-3.3–2.8)	0.950
Male sex (boys vs girls)	40	15.1 (7.1)	40	14.6 (6.4)	0.5 (-2.4–3.6)	0.806
Allergic rhinitis (yes vs no)	14	13.6 (6.0)	66	15.1 (6.9)	-1.5 (-5.4–2.5)	0.577

\*Includes the 81 children who returned the symptom diary out of the 82 enrolled. \*\*Mann-Whitney U-test.

\*\*\*The findings of *S. pneumoniae*, *H. influenzae* or *M. catarrhalis* in the nasal rigid endoscopic swab culture taken at an early phase of an acute respiratory infection.



**Fig. 5. Recovery of symptoms of acute respiratory infection in children according to the findings of pathogenic bacteria in endoscopic nasal middle meatal samples taken at an early phase of a respiratory infection ( $P = 0.014$  for the difference, log rank test).**

## 6 Discussion

According to the present studies, imaging examinations are of no value during acute uncomplicated rhinosinusitis in children. Incidental radiological paranasal sinus abnormalities are common even in healthy children without intention to seek medical help for any reason, and almost all children have paranasal sinus abnormalities during acute respiratory infection. These abnormalities resolve mainly without intervention. Antimicrobials do not give any benefit compared to placebo during acute respiratory infection with radiological rhinosinusitis. Cultures of middle meatal samples seem to predict prolonged duration of respiratory infection, since children with *S. pneumoniae*, *H. influenzae* or *M. catarrhalis* had a longer duration of common cold than children from whom these bacteria were not found. Further studies are needed to clarify whether this sampling method could be used as a diagnostic test to sort out the children who would benefit from antimicrobial treatment.

Despite the presence of extensive literature on sinusitis in children, actual evidence and data on the value of diagnostics of acute uncomplicated sinusitis are limited. According to the Clinical Practice Guideline of American Academy of Pediatrics, physical examination is not helpful in the diagnosis of acute rhinosinusitis in children, since the findings are similar in patients with uncomplicated viral rhinosinusitis and in patients with bacterial acute rhinosinusitis. It is also argued that imaging studies are not necessary to confirm a diagnosis of clinical acute rhinosinusitis in children  $\leq 6$  years of age. The need for radiographs as a confirmatory test of acute rhinosinusitis in children older than 6 years with persistent symptoms and for all children (regardless of age) with severe symptoms is controversial. (4) We did not find the age of the children to affect the radiologic findings, and our findings are thus in concordance with the American College of Radiology and the Sinus and Allergy Health Partnership, who do not recommend radiologic examinations for the diagnosis of acute uncomplicated sinusitis in any age group. (195,196) The Consensus Meetings of Rhinosinusitis in Children (Brussels, 1996) argue that the diagnosis is usually made on clinical grounds alone, but imaging of the sinuses may be indicated in selected patients. (12)

One important limitation of using imaging examinations as a diagnostic method of rhinosinusitis is the occurrence of incidental changes in the paranasal sinuses in children with radiographies taken for purposes other than the diagnosis of sinus disease. The

prevalence of incidental paranasal sinus abnormalities in our survey was similar to or slightly higher than was to be expected based on a review of the literature, which consisted of reports on MRI or CT performed on selected children hospitalised for indications other than sinus problems. In some series, the sinus abnormalities were more common in children with symptoms of recent respiratory infection. (131,137–139) Our findings are in concordance with the results that failed to show any differences in the frequency of incidental sinus findings in children with recent common cold compared to those without. (133,135,136) Our study is the only survey concerning healthy children without neurological or ophthalmological problems, and also the first prospective longitudinal follow-up study comparing MRI findings to respiratory symptoms.

Another limitation of imaging in the diagnostics of acute rhinosinusitis in children is the high frequency of radiological changes during any viral upper respiratory infection. Previously, common cold was widely thought to affect only the nasal passages and not the sinuses (197), but we found radiological paranasal sinus abnormalities to be common in children with common cold. This is in accordance with the surveys concerning adults with common cold (11,47,62) and with the CT study of children with purulent rhinitis of short duration (149). In the study of Schwartz *et al.*, CT of paranasal sinuses of children was taken after irrigation of nasal cavities with normal saline (made for diagnostic and therapeutic reasons), and the authors concluded that these paranasal abnormalities may have contributed to or been the sole cause of maxillary sinus effusions. (149)

In our study, abnormal MRI findings improved significantly in two weeks, although most of the children still had major abnormalities in their sinuses at the follow-up examination, as in the studies done on adults. (11,47) In the study of Leopold *et al.*, adults with clinically and radiographically diagnosed acute bacterial rhinosinusitis had paranasal sinus abnormalities for more than 8 weeks despite antimicrobial treatment. (145) The severity of the paranasal abnormalities was related to the severity of respiratory symptoms. Nasal obstruction, nasal discharge, and fever as individual symptoms also significantly correlated with the MRI scores. A correlation has also been found between nasal or head congestion (11) and the high mean severity scores of purulent rhinitis (47) and radiological sinusitis in the common cold studies done on adult patients.

The present finding of antimicrobials being no better than placebo in improving the clinical status of the children with radiological rhinosinusitis indicates that acute viral and bacterial rhinosinusitis cannot be differentiated with this method. Kaiser *et al.* also reported a lack of significant benefit from azithromycin compared to placebo in a study of adults with symptoms of common cold and radiologically confirmed maxillary sinusitis. (170)

This leaves us with the difficult problem of how to identify the children with acute respiratory infection who suffer from bacterial infection and would benefit from antimicrobial treatment. One possible solution could be middle meatal bacterial cultures, especially in children older than 6 years. The correlations between culture samples from the middle meatus and the maxillary sinus have been good in studies on adults with acute and chronic maxillary sinusitis (16,162–164) and also in children with chronic sinusitis (165). In our study, children with *S. pneumoniae*, *H. influenzae* or *M. catarrhalis* in the middle meatal bacterial culture had a significantly longer duration of common cold symptoms than children without these bacteria. This finding is clinically important, since the median duration of common cold was 3.6 days longer in a group with these bacteria

compared to a group without these bacteria in the middle meatus (16.7 days vs 13.1 days, respectively). We did not obtain bacterial cultures from the paranasal sinuses, and we therefore do not know if middle meatal culture correlates with paranasal sinus cultures.

Pathogenic bacteria have also been found to be common in the middle meatus in children without sinus symptoms. Gordts *et al.* reported that 92% of 3- to 4-year-old children undergoing ear, nose and throat surgery and 70% of those undergoing other surgical procedures had *S. pneumoniae*, *H. influenzae* or *M. catarrhalis* in their middle meatus. (80,198) In our study, altogether 41% children with acute respiratory infection had pathogenic bacteria in the middle meatus, but the children in our study were older (mean age 9.8 years) than those in the studies of Gordts. In our study, the children without pathogenic bacteria in the middle meatus tended to be older than those with pathogenic bacteria. Pathogenic bacteria are seldom seen in the middle meatus of healthy adults. (160)

Endoscopic control in the sampling of middle meatal secretion is essential, since middle meatal cultures obtained without endoscopy are not specific for the identification of the bacteria responsible for acute rhinosinusitis. These cultures are frequently contaminated with *S. aureus* and do not correlate well with the results of paranasal sinus aspiration. (199) The Consensus Meeting of Management of Rhinosinusitis in Children could not reach any consensus regarding whether middle meatal cultures could substitute for sinus punctures. (12) A randomised controlled trial is therefore needed to evaluate the clinical value of taking a swab culture from the middle meatus to identify the children who would benefit from antimicrobial treatment among the children with acute respiratory infection.

Nasopharyngeal cultures correlate with the duration of acute respiratory symptoms in adults. (200) Kaiser *et al.* found that adults with uncomplicated common cold had a more protracted course of illness when *S. pneumoniae*, *H. influenzae* or *M. catarrhalis* was obtained from the nasopharynx. (200) In their other study, they found antimicrobials to be effective in adult patients with sinusitis or common cold when *S. pneumoniae*, *H. influenzae* or *M. catarrhalis* was found in their nasopharynx. (170) In our study, *S. pneumoniae* was much more often found in the nasopharynx than in the nasal middle meatus, and the results of nasopharyngeal culture did not correlate with the duration of symptoms. Because of the high carriage rate of pathogenic bacteria in the nasopharynx, this is not a suitable method for screening children for antimicrobial treatment.

The thesis consists of four prospectively designed reports, which all had a separate study population, and the research questions were pre-specified. Three of the papers were observational descriptive cohort studies (I,II,IV) and one a randomised, double-blinded clinical study (III). The age of the study children ranged from 4 to 13 years, and 47% of them were girls. The samples of the studies I and IV consisted of volunteers and could thus represent the part of the general population willing to participate in research. Hence, the populations of these two studies can be healthier or sicker than normal, which may affect the generalisability of the results. In the studies II and III, we had consecutive samples of sick children seen at the clinic. The duration of symptoms in our patients was 6.5 days (SD 4.4), which represents only the first days of rhinosinusitis (according to the definition, the duration of acute rhinosinusitis is up to 4 weeks). Microbiological samples from the maxillary sinuses would have given us much more information, but they were

not obtained because maxillary puncture is invasive and unethical in children with mild symptoms and signs.

Based on these findings, it is recommended that radiological examinations of paranasal sinuses should not be made in children with symptoms of acute rhinosinusitis. Children with pathological imaging findings as an incidental finding or during respiratory infection should not be treated with antimicrobials without any other evidence of bacterial etiology.

## 7 Conclusions

1. Radiological abnormalities of the paranasal sinuses are common even in healthy children without specific symptoms of sinus infections. These incidental radiological abnormalities are not an indication for antimicrobial treatment.
2. Radiological abnormalities of the paranasal sinuses are very common during upper respiratory infection, and most of them resolve spontaneously without antimicrobial treatment.
3. Ultrasonography or radiography should not be used alone as indications for antimicrobial treatment in children with symptoms of acute rhinosinusitis.
4. Pathogenic bacteria (*S. pneumoniae*, *H. influenzae* or *M. catarrhalis*) in the nasal middle meatus predict a longer duration of upper respiratory infection.

## References

1. McCaig LF & Hughes JM (1995) Trends in antimicrobial drug prescribing among office-based physicians in the United States. *JAMA* 273(3): 214–219.
2. Monto AS & Ullman BM (1974) Acute respiratory illness in an American community. The Tecumseh study. *JAMA* 227(2): 164–169.
3. Wald ER, Guerra N & Byers C (1991) Frequency and severity of infections in day care: three-year follow-up. *J Pediatr* 118: 509–514.
4. Clinical practice guideline: management of sinusitis (2001) *Pediatrics* 108(3): 798–808.
5. Wald ER, Guerra N & Byers C (1991) Upper respiratory tract infections in young children: duration of and frequency of complications. *Pediatrics* 87(2): 129–133.
6. Reisman HA (1931) Sinusitis in children. *Arch Pediatr* 48: 283–292.
7. Marantz BC (1931) The importance of diagnosis and treating sinusitis in infants and children. *Arch Pediatr* 48: 365–374.
8. Björkwall T (1950) Bacteriological examinations in maxillary sinusitis. *Acta Otolaryngol Suppl* 83: 9–58.
9. Berg O, Carenfelt C & Kronvall G (1988) Bacteriology of maxillary sinusitis in relation to character of inflammation and prior treatment. *Scand J Infect Dis* 20(5): 511–516.
10. Lemere HB (1922) The diagnosis of nasal sinus disease in children. *Arch Pediatr* 39: 601–606.
11. Gwaltney JM Jr, Phillips CD, Miller RD & Riker DK (1994) Computed tomographic study of the common cold. *N Engl J Med* 330(1): 25–30.
12. Clement PA, Bluestone CD, Gordts F, Lusk RP, Otten FW, Goossens H *et al.* (1998) Management of rhinosinusitis in children: consensus meeting, Brussels, Belgium, September 13, 1996. *Arch Otolaryngol Head Neck Surg* 124(1): 31–34.
13. van Buchem FL, Peeters MF & Knottnerus JA (1992) Maxillary sinusitis in children. *Clin Otolaryngol* 17(1): 49–53.
14. Wald ER, Chiponis D & Ledesma-Medina J (1986) Comparative effectiveness of amoxicillin and amoxicillin-clavulanate potassium in acute paranasal sinus infections in children: a double-blind, placebo-controlled trial. *Pediatrics* 77(6): 795–800.
15. Garbutt JM, Goldstein M, Gellman E, Shannon W & Littenberg B (2001) A randomized, placebo-controlled trial of antimicrobial treatment for children with clinically diagnosed acute sinusitis. *Pediatrics* 107(4): 619–625.
16. Talbot GH, Kennedy DW, Scheld WM & Granito K (2001) Rigid nasal endoscopy versus sinus puncture and aspiration for microbiologic documentation of acute bacterial maxillary sinusitis. *Clin Infect Dis* 33(10): 1668–1675.

17. Nash DR, Harman J, Wald ER & Kelleher KJ (2002) Antibiotic prescribing by primary care physicians for children with upper respiratory tract infections. *Arch Pediatr Adolesc Med* 156(11): 1114–1119.
18. Schwartz RH, Freij BJ, Ziai M & Sheridan MJ (1997) Antimicrobial prescribing for acute purulent rhinitis in children: a survey of pediatricians and family practitioners. *Pediatr Infect Dis J* 16(2): 185–190.
19. Cristino JM (1999) Correlation between consumption of antimicrobials in humans and development of resistance in bacteria. *Int J Antimicrob Agents* 12(3): 199–202.
20. Poole MD, Jacobs MR, Anon JB, Marchant CD, Hoberman A & Harrison CJ (2002) Antimicrobial guidelines for the treatment of acute bacterial rhinosinusitis in immunocompetent children. *Int J Pediatr Otorhinolaryngol* 63(1): 1–13.
21. Hytönen M, Atula T & Pitkäranta A (2000) Complications of acute sinusitis in children. *Acta Otolaryngol Suppl* 543: 154–157.
22. Giannoni C, Sulek M (1998) Friedman EM. Intracranial complications of sinusitis: a pediatric series. *Am J Rhinol* 12(3): 173–178.
23. Pitkäranta A, Atula T, Lindahl P, Saxen H & Malmberg H (2000) Unilateral blindness in a child with acute sinusitis. *Rhinology* 38(1): 43–44.
24. Wald ER, Pang D, Milmoie GJ & Schramm VL Jr (1981) Sinusitis and its complications in the pediatric patient. *Pediatr Clin North Am* 28(4): 777–796.
25. Hengerer AS (1984) Embryologic development of the sinuses. *Ear Nose Throat J* 63(4): 134–136.
26. Wang RG, Jiang SC & Gu R (1994) The cartilaginous nasal capsule and embryonic development of human paranasal sinuses. *J Otolaryngol* 23(4): 239–243.
27. Wolf G, Anderhuber W & Kuhn F (1993) Development of the paranasal sinuses in children: implications for paranasal sinus surgery. *Ann Otol Rhinol Laryngol* 102(9): 705–711.
28. Barghouth G, Prior JO, Lepori D, Duvoisin B, Schnyder P & Gudinchet F (2002) Paranasal sinuses in children: size evaluation of maxillary, sphenoid, and frontal sinuses by magnetic resonance imaging and proposal of volume index percentile curves. *Eur Radiol* 12(6): 1451–1458.
29. Otten FW & Grote JJ (1988) Treatment of chronic maxillary sinusitis in children. *Int J Pediatr Otorhinolaryngol* 15(3): 269–278.
30. Clement PA, Bijloos J, Kaufman L, Lauwers L, Maes JJ, Van Der Veken P *et al.* (1989) Incidence and etiology of rhinosinusitis in children. *Acta Otorhinolaryngol Belg* 43(5): 523–543.
31. Ummat S, Riding M & Kirkpatrick D (1992) Development of the ostiomeatal unit in childhood: a radiological study. *J Otolaryngol* 21(5): 307–314.
32. Weiglein A, Anderhuber W & Wolf G (1992) Radiologic anatomy of the paranasal sinuses in the child. *Surg Radiol Anat* 14(4): 335–339.
33. Reittner P, Doerfler O, Goritschnig T, Tillich M, Koele W, Stammberger H *et al.* (2001) Magnetic resonance imaging patterns of the development of the sphenoid sinus: a review of 800 patients. *Rhinology* 39(3): 121–124.
34. Graney DO & Rice DH (1998) Paranasal sinuses. Anatomy. In: Cummings CW, Fredrickson JM, Harker LA, Krause CJ, Scheller DE, Richardson MA, editors. *Otolaryngology, Head and Neck Surgery*. Mosby 1059–1064.
35. Drettner B (1980) Pathophysiology of paranasal sinuses with clinical implications. *Clin Otolaryngol* 5(4): 277–284.
36. Wald ER (1994) Sinusitis in children. *Isr J Med Sci* 30(5-6): 403–407.
37. Parsons DS & Wald ER (1996) Otitis media and sinusitis: similar diseases. *Otolaryngol Clin North Am* 29(1): 11–25.

38. Seppa J (1993) Mucociliary transport of the eustachian tube in chronic otitis media. Kuopio University Publications D. Medical Sciences 22.
39. Nuutinen J, Kärjä J & Karjalainen P (1983) Measurements of impaired mucociliary activity in children. *Eur J Respir Dis Suppl* 128 (Pt 2): 454–456.
40. Nuutinen J (1985) Activation of the impaired nasal mucociliary transport in children: preliminary report. *Int J Pediatr Otorhinolaryngol* 10(1): 47–52.
41. Meltzer EO, Hamilos DL, Hadley JA, Lanza DC, Marple BF, Nicklas RA *et al.* (2004) Rhinosinusitis: establishing definitions for clinical research and patient care. *J Allergy Clin Immunol* 114(6 Suppl): 155–212.
42. Nash D & Wald E (2001) Sinusitis. *Pediatr Rev* 22(4): 111–117.
43. Clement PA, Bluestone CD, Gordts F, Lusk RP, Otten FW, Goossens H *et al.* (1999) Management of rhinosinusitis in children. *Int J Pediatr Otorhinolaryngol* 49 Suppl 1: S95–100.
44. Gwaltney JM Jr (1996) Acute community-acquired sinusitis. *Clin Infect Dis* 23(6):1209–1223.
45. Hopp R & Cooperstock M (1997) Medical management of sinusitis in pediatric patients. *Curr Probl Pediatr* 27(5): 178–186.
46. Turner BW, Cail WS, Hendley JO, Hayden FG, Doyle WJ, Sorrentino JV *et al.* (1992) Physiologic abnormalities in the paranasal sinuses during experimental rhinovirus colds. *J Allergy Clin Immunol* 90(3 Pt 2): 474–478.
47. Puhakka T, Mäkelä MJ, Alanen A, Kallio T, Korsoff L, Arstila P *et al.* (1998) Sinusitis in the common cold. *J Allergy Clin Immunol* 102(3): 403–408.
48. Evans FO Jr, Sydnor JB, Moore WE, Moore GR, Manwaring JL, Brill AH *et al.* (1975) Sinusitis of the maxillary antrum. *N Engl J Med* 293(15): 735–739.
49. Turner RB (1997) Epidemiology, pathogenesis, and treatment of the common cold. *Ann Allergy Asthma Immunol* 78(6):531–539.
50. Gwaltney JM Jr, Moskalski PB & Hendley JO (1978) Hand-to-hand transmission of rhinovirus colds. *Ann Intern Med* 88(4): 463–467.
51. Heikkinen T & Jarvinen A (2003) The common cold. *Lancet* 361(9351): 51–59.
52. Staunton DE, Merluzzi VJ, Rothlein R, Barton R, Marlin SD & Springer TA (1989) A cell adhesion molecule, ICAM-1, is the major surface receptor for rhinoviruses. *Cell* 56(5): 849–853.
53. Greve JM, Davis G, Meyer AM, Forte CP, Yost SC, Marlor CW *et al.* (1989) The major human rhinovirus receptor is ICAM-1. *Cell* 56(5): 839–847.
54. Winther B, Gwaltney JM, Jr., Mygind N, Turner RB & Hendley JO (1986) Sites of rhinovirus recovery after point inoculation of the upper airway. *JAMA* 256(13): 1763–1767.
55. Rihkanen H, Carpen O, Roivainen M, Vaheri A & Pitkäranta A (2004) Rhinovirus in adenoid tissue. *Int J Pediatr Otorhinolaryngol* 68(7): 903–908.
56. Turner RB, Winther B, Hendley JO, Mygind N & Gwaltney JM Jr (1984) Sites of virus recovery and antigen detection in epithelial cells during experimental rhinovirus infection. *Acta Otolaryngol Suppl* 413: 9–14.
57. Arruda E, Boyle TR, Winther B, Pevear DC, Gwaltney JM Jr & Hayden FG (1995) Localization of human rhinovirus replication in the upper respiratory tract by in situ hybridization. *J Infect Dis* 171(5): 1329–1333.
58. van Kempen M, Bachert C & van Cauwenberge P (1999) An update on the pathophysiology of rhinovirus upper respiratory tract infections. *Rhinology* 37(3): 97–103.
59. Corne JM, Lau L, Scott SJ, Davies R, Johnston SL & Howarth PH (2001) The relationship between atopic status and IL-10 nasal lavage levels in the acute and persistent inflammatory response to upper respiratory tract infection. *Am J Respir Crit Care Med* 163(5): 1101–1107.

60. Alho OP, Karttunen TJ, Karttunen R, Tuokko H, Koskela M & Uhari M (2003) Lymphocyte and mast cell counts are increased in the nasal mucosa in symptomatic natural colds. *Clin Exp Immunol* 131(1): 138–142.
61. Johnston SL, Bardin PG & Pattemore PK (1993) Viruses as precipitants of asthma symptoms. III. Rhinoviruses: molecular biology and prospects for future intervention. *Clin Exp Allergy* 23(4): 237–246.
62. Alho OP, Ylitalo K, Jokinen K, Laitinen J, Suramo I, Tuokko H *et al.* (2001) The common cold in patients with a history of recurrent sinusitis: increased symptoms and radiologic sinusitislike findings. *J Fam Pract* 50(1): 26–31.
63. Pitkäranta A, Starck M, Savolainen S, Pöyry T, Suomalainen I, Hyypiä T *et al.* (2001) Rhinovirus RNA in the maxillary sinus epithelium of adult patients with acute sinusitis. *Clin Infect Dis* 33(6): 909–911.
64. Gwaltney JM (2002) Clinical significance and pathogenesis of viral respiratory infections. *Am J Med* 112 Suppl 6A: 13S–18S.
65. Gwaltney JM, Jr., Hendley JO, Phillips CD, Bass CR, Mygind N & Winther B (2000) Nose blowing propels nasal fluid into the paranasal sinuses. *Clin Infect Dis* 30(2): 387–391.
66. Giebink GS (1994) Childhood sinusitis: pathophysiology, diagnosis and treatment. *Pediatr Infect Dis J* 13(1 Suppl 1): S55–S58.
67. Rautiainen M, Nuutinen J, Kiukaanniemi H & Collan Y (1992) Ultrastructural changes in human nasal cilia caused by the common cold and recovery of ciliated epithelium. *Ann Otol Rhinol Laryngol* 101(12): 982–987.
68. Pedersen M, Sakakura Y, Winther B, Brofeldt S & Mygind N (1983) Nasal mucociliary transport, number of ciliated cells, and beating pattern in naturally acquired common colds. *Eur J Respir Dis Suppl* 128 (Pt 1): 355–365.
69. Kärjä J & Nuutinen J (1983) Immotile cilia syndrome in children. *Int J Pediatr Otorhinolaryngol* 5(3): 275–279.
70. Conway PJ & Jones NS (2000) The nose and nitric oxide: a review. *Clin Otolaryngol* 25(5): 337–341.
71. Sanders SP, Proud D, Permutt S, Siekierski ES, Yachechko R & Liu MC (2004) Role of nasal nitric oxide in the resolution of experimental rhinovirus infection. *J Allergy Clin Immunol* 113(4): 697–702.
72. Lindberg S, Cervin A & Runer T (1997) Low levels of nasal nitric oxide (NO) correlate to impaired mucociliary function in the upper airways. *Acta Otolaryngol* 117(5): 728–734.
73. Korppi M (2002) Mixed microbial aetiology of community-acquired pneumonia in children. *APMIS* 110(7-8): 515–522.
74. Hietala J, Uhari M, Tuokko H & Leinonen M (1989) Mixed bacterial and viral infections are common in children. *Pediatr Infect Dis* 8(10): 683–686.
75. Arruda E, Pitkäranta A, Witek TJ Jr, Doyle CA & Hayden FG (1997) Frequency and natural history of rhinovirus infections in adults during autumn. *J Clin Microbiol* 35(11): 2864–2868.
76. Mäkelä MJ, Puhakka T, Ruuskanen O, Leinonen M, Saikku P, Kimpimäki M *et al.* (1998) Viruses and bacteria in the etiology of the common cold. *J Clin Microbiol* 36(2): 539–542.
77. Pitkäranta A & Hayden FG (1998) Rhinoviruses: important respiratory pathogens. *Ann Med* 30(6): 529–537.
78. Nokso-Koivisto J, Pitkäranta A, Blomqvist S, Jokinen J, Kleemola M, Takala A *et al.* (2002) Viral etiology of frequently recurring respiratory tract infections in children. *Clin Infect Dis* 35(5): 540–546.
79. Alho OP (2003) Paranasal sinus bony structures and sinus functioning during viral colds in subjects with and without a history of recurrent sinusitis. *Laryngoscope* 113(12): 2163–2168.

80. Gordts F, Abu Nasser I, Clement PA, Pierard D & Kaufman L (1999) Bacteriology of the middle meatus in children. *Int J Pediatr Otorhinolaryngol* 48(2): 163–167.
81. Box QT, Cleveland RT & Willard CY (1961) Bacterial flora of the upper respiratory tract. *Am J Dis Child* 102: 39–47.
82. Jousimies-Somer HR, Savolainen S & Ylikoski JS (1989) Comparison of the nasal bacterial floras in two groups of healthy subjects and in patients with acute maxillary sinusitis. *J Clin Microbiol* 27(12): 2736–2743.
83. Axelsson A & Brorson JE (1973) The correlation between bacteriological findings in the nose and maxillary sinus in acute maxillary sinusitis. *Laryngoscope* 83(12): 2003–2011.
84. Gwaltney JM Jr & Hayden FG (1992) Psychological stress and the common cold. *N Engl J Med* 326(9): 644–645.
85. Arruda LK, Mimica IM, Sole D, Weckx LL, Schoettler J, Heiner DC *et al.* (1990) Abnormal maxillary sinus radiographs in children: do they represent bacterial infection? *Pediatrics* 85(4): 553–558.
86. Wald ER, Milmoie GJ, Bowen A, Ledesma-Medina J, Salamon N & Bluestone CD (1981) Acute maxillary sinusitis in children. *N Engl J Med* 304(13): 749–754.
87. Wald ER, Reilly JS, Casselbrant M, Ledesma-Medina J, Milmoie GJ, Bluestone CD *et al.* (1984) Treatment of acute maxillary sinusitis in childhood: a comparative study of amoxicillin and cefaclor. *J Pediatr* 104(2): 297–302.
88. Jousimies-Somer HR, Savolainen S & Ylikoski JS (1988) Bacteriological findings of acute maxillary sinusitis in young adults. *J Clin Microbiol* 26(10): 1919–1925.
89. Lystad A, Berdal P & Lund-Iversen L (1964) The bacterial flora of sinusitis with an in vitro study of the bacterial resistance to antibiotics. *Acta Otolaryngol* 12:suppl.
90. Pitkäranta A, Arruda E, Malmberg H & Hayden FG (1997) Detection of rhinovirus in sinus brushings of patients with acute community-acquired sinusitis by reverse transcription-PCR. *J Clin Microbiol* 35(7): 1791–1793.
91. Maresh MM & Washburn AH (1940) Paranasal sinuses from birth to late adolescence: clinical and roentgenographic evidence of infection. *Am J Dis Child* 60: 841–861.
92. Maresh MM (1940) Paranasal sinuses from birth to late adolescence: size of the paranasal sinuses as observed in routine posteroanterior roentgenograms. *Am J Dis Child* 60: 55–78.
93. Diamant MJ (1992) The diagnosis of sinusitis in infants and children: x-ray, computed tomography, and magnetic resonance imaging. *Diagnostic imaging of pediatric sinusitis. J Allergy Clin Immunol* 90(3 Pt 2): 442–444.
94. O'Brien KL, Dowell SF, Schwartz B, Marcy SM, Phillips WR & Gerber MA (1998) Acute Sinusitis - Principles of Judicious Use of Antimicrobial Agents. *Pediatrics* 101: 174–177.
95. Rosenstein N, Phillips WR, Gerber M.A., Marcy SM, Schwartz B & Dowell SF (1998) The Common Cold - Principles of Judicious Use of Antimicrobial Agents. *Pediatrics* 101: 181–184.
96. Ueda D & Yoto Y (1996) The ten-day mark as a practical diagnostic approach for acute paranasal sinusitis in children. *Pediatr Infect Dis J* 15(7): 576–579.
97. Alho OP, Koivu M, Sorri M & Rantakallio P (1990) Risk factors for recurrent acute otitis media and respiratory infection in infancy. *Int J Pediatr Otorhinolaryngol* 19(2): 151–161.
98. Stenstrom C & Ingvarsson L (1997) Otitis-prone children and controls: a study of possible predisposing factors. 1. Heredity, family background and perinatal period. *Acta Otolaryngol* 117(1): 87–93.
99. Rachelefsky GS, Goldberg M, Katz RM, Boris G, Gyepes MT, Shapiro MJ *et al.* (1978) Sinus disease in children with respiratory allergy. *J Allergy Clin Immunol* 61(5): 310–314.
100. Alho OP, Karttunen TJ, Karttunen R, Tuokko H, Koskela M, Suramo I *et al.* (2003) Subjects with allergic rhinitis show signs of more severely impaired paranasal sinus functioning during viral colds than nonallergic subjects. *Allergy* 58(8): 767–771.

101. Shapiro GG (1985) Role of allergy in sinusitis. *Pediatr Infect Dis* 4(6 Suppl): S55–S59.
102. Furukawa CT (1992) The role of allergy in sinusitis in children. *J Allergy Clin Immunol* 90(3 Pt 2): 515–517.
103. Friedman R, Ackerman M, Wald E, Casselbrant M, Friday G & Fireman P (1984) Asthma and bacterial sinusitis in children. *J Allergy Clin Immunol* 74(2): 185–189.
104. Goldsmith AJ & Rosenfeld RM (2003) Treatment of pediatric sinusitis. *Pediatr Clin North Am* 50(2): 413–426.
105. Lund VJ (1994) Bacterial sinusitis: etiology and surgical management. *Pediatr Infect Dis J* 13(1 Suppl 1): S58–S63.
106. Bardin PG, Van Heerden BB & Joubert JR (1990) Absence of pulmonary aspiration of sinus contents in patients with asthma and sinusitis. *J Allergy Clin Immunol* 86(1): 82–88.
107. Rachelefsky GS, Katz RM & Siegel SC (1982) Chronic sinusitis in children with respiratory allergy: the role of antimicrobials. *J Allergy Clin Immunol* 69(4): 382–387.
108. Tamaoki J, Kadota J & Takizawa H (2004) Clinical implications of the immunomodulatory effects of macrolides. *Am J Med* 117 Suppl 9A: 5S–11S.
109. Parnham MJ (2005) Immunomodulatory effects of antimicrobials in the therapy of respiratory tract infections. *Curr Opin Infect Dis* 18(2): 125–131.
110. Amsden GW (2005) Anti-inflammatory effects of macrolides--an underappreciated benefit in the treatment of community-acquired respiratory tract infections and chronic inflammatory pulmonary conditions? *J Antimicrob Chemother* 55(1): 10–21.
111. Shapiro GG, Virant FS, Furukawa CT, Pierson WE & Bierman CW (1991) Immunologic defects in patients with refractory sinusitis. *Pediatrics* 87(3): 311–316.
112. Antila J (1999) Acute frontal sinusitis in adults. *Ann Univ Turkuensis D* 355.
113. Herrmann BW & Forsen JW Jr (2004) Simultaneous intracranial and orbital complications of acute rhinosinusitis in children. *Int J Pediatr Otorhinolaryngol* 68(5): 619–625.
114. Lerner DN, Choi SS, Zalzal GH & Johnson DL (1995) Intracranial complications of sinusitis in childhood. *Ann Otol Rhinol Laryngol* 104(4 Pt 1): 288–293.
115. Wald ER (1983) Acute sinusitis and orbital complications in children. *Am J Otolaryngol* 4(6): 424–427.
116. Ioannidis JP & Lau J (2001) Technical report: evidence for the diagnosis and treatment of acute uncomplicated sinusitis in children: a systematic overview. *Pediatrics* 108(3): E57.
117. Wald ER (1988) Acute sinusitis in children. *Adv Otolaryngol Head Neck Surgery* 2. Year Booc Medical Publishers Inc. 165–188.
118. Berg O & Carenfelt C (1998) Analysis of symptoms and clinical signs in the maxillary sinus empyema. *Acta Otolaryngol* 105(3-4): 343–349.
119. Fireman P (1992) Diagnosis of sinusitis in children: emphasis on the history and physical examination. *J Allergy Clin Immunol* 90(3 Pt 2): 433–436.
120. Gohd RS (1954) The common cold. *N Engl J Med* 250(16): 687–691.
121. Hays GC & Mullard JE (1972) Can nasal bacterial flora be predicted from clinical findings? *Pediatrics* 49(4): 596–599.
122. Winther B, Brofeldt S, Gronborg H, Mygind N, Pedersen M & Vejlsgaard R (1984) Study of bacteria in the nasal cavity and nasopharynx during naturally acquired common colds. *Acta Otolaryngol* 98(3-4): 315–320.
123. Mainous AG, III, Hueston WJ & Eberlein C (1997) Colour of respiratory discharge and antibiotic use. *Lancet* 350(9084): 1077.
124. Wald ER (1991) Purulent nasal discharge. *Pediatr Infect Dis J* 10(4): 329–333.
125. McAlister WH & Kronemer K (1999) Imaging of sinusitis in children. *Pediatr Infect Dis J* 18(11): 1019–1020.
126. Axelsson A & Runze U (1976) Symptoms and signs of acute maxillary sinusitis. *ORL J Otorhinolaryngol Relat Spec* 38(5): 298–308.

127. Jannert M, Andreasson L, Helin I & Pettersson H (1982) Acute sinusitis in children--symptoms, clinical findings and bacteriology related to initial radiologic appearance. *Int J Pediatr Otorhinolaryngol* 4(2): 139–148.
128. Axelsson A & Jensen C (1974) The roentgenologic demonstration of sinusitis. *Am J Roentgenol Radium Ther Nucl Med* 122(3): 621–627.
129. Kuuliala I & Revonta M (1990) Occipito-mental side projection radiography in childhood maxillary sinusitis. *Int J Pediatr Otorhinolaryngol* 18(3): 221–225.
130. Uhari M, Lanning P, Kouvalainen K & Åkerblom HK (1977) Lasten poskionteloiden patologisen röntgenlöydöksen yleisyys [Incidence of pathological x-ray findings in the maxillary sinuses of children]. *Duodecim* 93(6): 372–377.
131. Kovatch AL, Wald ER, Ledesma-Medina J, Chiponis DM & Bedingfield B (1984) Maxillary sinus radiographs in children with nonrespiratory complaints. *Pediatrics* 73(3): 306–308.
132. Haapaniemi J (1997) Comparison of ultrasound and X-ray maxillary sinus findings in school-aged children. *Ear Nose Throat J* 76(2): 102–106.
133. Glasier CM, Ascher DP & Williams KD (1986) Incidental paranasal sinus abnormalities on CT of children: clinical correlation. *AJNR Am J Neuroradiol* 7(5): 861–864.
134. Diamant MJ, Senac MO, Jr., Gilsanz V, Baker S, Gillespie T & Larsson S (1987) Prevalence of incidental paranasal sinuses opacification in pediatric patients: a CT study. *J Comput Assist Tomogr* 11(3): 426–431.
135. Glasier CM, Mallory GB Jr & Steele RW (1989) Significance of opacification of the maxillary and ethmoid sinuses in infants. *J Pediatr* 114(1): 45–50.
136. Lesserson JA, Kieserman SP & Finn DG (1994) The radiographic incidence of chronic sinus disease in the pediatric population. *Laryngoscope* 104(2): 159–166.
137. Manning SC, Biavati MJ & Phillips DL (1996) Correlation of clinical sinusitis signs and symptoms to imaging findings in pediatric patients. *Int J Pediatr Otorhinolaryngol* 37(1): 65–74.
138. Gordts F, Clement PA, Destryker A, Desprechins B & Kaufman L (1997) Prevalence of sinusitis signs on MRI in a non-ENT paediatric population. *Rhinology* 35(4): 154–157.
139. Lim WK, Ram B, Fasulakis S & Kane KJ (2003) Incidental magnetic resonance image sinus abnormalities in asymptomatic Australian children. *J Laryngol Otol* 117(12): 969–972.
140. Tatli MM, San I & Karaoglanoglu M (2001) Paranasal sinus computed tomographic findings of children with chronic cough. *Int J Pediatr Otorhinolaryngol* 60(3): 213–217.
141. Jones RL, Crowe P, Chavda SV & Pahor AL (1997) The incidence of sinusitis in patients with multiple sclerosis. *Rhinology* 35(3): 118–119.
142. Patel K, Chavda SV, Violaris N & Pahor AL (1996) Incidental paranasal sinus inflammatory changes in a British population. *J Laryngol Otol* 110(7): 649–651.
143. Havas TE, Motbey JA & Gullane PJ (1988) Prevalence of incidental abnormalities on computed tomographic scans of the paranasal sinuses. *Arch Otolaryngol Head Neck Surg* 114(8): 856–859.
144. Tarp B, Fiirgaard B, Christensen T, Jensen JJ & Black FT (2000) The prevalence and significance of incidental paranasal sinus abnormalities on MRI. *Rhinology* 38(1): 33–38.
145. Leopold DA, Stafford CT, Sod EW, Szeverenyi NM, Allison JD, Phipps RJ *et al.* (1994) Clinical course of acute maxillary sinusitis documented by sequential MRI scanning. *Am J Rhinology* 8(1): 19–28.
146. van der Veken PJ, Clement PA, Buisseret T, Desprechins B, Kaufman L & Derde MP (1990) CT-scan study of the incidence of sinus involvement and nasal anatomic variations in 196 children. *Rhinology* 28(3): 177–184.
147. Kogutt MS & Swischuk LE (1973) Diagnosis of sinusitis in infants and children. *Pediatrics* 52(1): 121–124.

148. Barlan IB, Erkan E, Bakir M, Berrak S & Basaran MM (1997) Intranasal budesonide spray as an adjunct to oral antibiotic therapy for acute sinusitis in children. *Ann Allergy Asthma Immunol* 78(6): 598–601.
149. Schwartz RH, Pitkäranta A & Winther B (2001) Computed tomography imaging of the maxillary and ethmoid sinuses in children with short-duration purulent rhinorrhea. *Otolaryngol Head Neck Surg* 124(2): 160–163.
150. Revonta M (1979) A-mode ultrasound of maxillary sinusitis in children. *Lancet* 1(8111): 320.
151. Reilly JS, Hotaling AJ, Chiponis D & Wald ER (1989) Use of ultrasound in detection of sinus disease in children. *Int J Pediatr Otorhinolaryngol* 17(3): 225–230.
152. Berg O & Carefelt C (1985) Etiological diagnosis in sinusitis: ultrasonography as clinical complement. *Laryngoscope* 95(7 Pt 1): 851–853.
153. Rohr AS, Spector SL, Siegel SC, Katz RM & Rachelefsky GS (1986) Correlation between A-mode ultrasound and radiography in the diagnosis of maxillary sinusitis. *J Allergy Clin Immunol* 78(1 Pt 1): 58–61.
154. Blomgren K, Hytönen M, Pellinen J, Relander M & Pitkäranta A (2002) Diagnostic accuracy of acute maxillary sinusitis in adults in primary care. *Scand J Prim Health Care* 20(1): 40–44.
155. Haapaniemi J & Laurikainen E (2001) Ultrasound and antral lavage in the examination of maxillary sinuses. *Rhinology* 39(1): 39–42.
156. Puhakka T, Heikkinen T, Mäkelä MJ, Alanen A, Kallio T, Korsoff L *et al.* (2000) Validity of ultrasonography in diagnosis of acute maxillary sinusitis. *Arch Otolaryngol Head Neck Surg* 126(12): 1482–1486.
157. Berger G, Steinberg DM, Popovtzer A & Ophir D (2005) Endoscopy versus radiography for the diagnosis of acute bacterial rhinosinusitis. *Eur Arch Otorhinolaryngol* 262(5): 416–422.
158. Klossek JM, Dubreuil L, Richet H, Richet B, Sedallian A & Beutter P (1996) Bacteriology of the adult middle meatus. *J Laryngol Otol* 110(9): 847–849.
159. Savolainen S, Ylikoski J & Jousimies-Somer H (1986) The bacterial flora of the nasal cavity in healthy young men. *Rhinology* 24(4): 249–255.
160. Gordts F, Halewyck S, Pierard D, Kaufman L & Clement PA (2000) Microbiology of the middle meatus: a comparison between normal adults and children. *J Laryngol Otol* 114(3): 184–188.
161. Nadel DM, Lanza DC & Kennedy DW (1999) Endoscopically guided sinus cultures in normal subjects. *Am J Rhinol* 13(2): 87–90.
162. Vogan JC, Bolger WE & Keyes AS (2000) Endoscopically guided sinonasal cultures: a direct comparison with maxillary sinus aspirate cultures. *Otolaryngol Head Neck Surg* 122(3): 370–373.
163. Gold SM & Tami TA (1997) Role of middle meatus aspiration culture in the diagnosis of chronic sinusitis. *Laryngoscope* 107(12 Pt 1): 1586–1589.
164. Araujo E, Palombini BC, Cantarelli V, Pereira A & Mariante A (2003) Microbiology of middle meatus in chronic rhinosinusitis. *Am J Rhinol* 17(1): 9–15.
165. Orobello PW, Jr., Park RI, Belcher LJ, Eggleston P, Lederman HM, Banks JR *et al.* (1991) Microbiology of chronic sinusitis in children. *Arch Otolaryngol Head Neck Surg* 117(9): 980–983.
166. Cools GH & Clement PA (1991) The use of a rigid nasal endoscope in children--with special interest in the middle meatus. *Acta Otorhinolaryngol Belg* 45(4): 399–404.
167. Tosca MA, Riccio AM, Marseglia GL, Caligo G, Pallestrini E, Ameli F *et al.* (2001) Nasal endoscopy in asthmatic children: assessment of rhinosinusitis and adenoiditis incidence, correlations with cytology and microbiology. *Clin Exp Allergy* 31(4): 609–615.

168. Ameli F, Castelnuovo P, Pagella F, Caligo G, Cerniglia M, Delu G *et al.* (2004) Nasal endoscopy in asthmatic children: clinical role in the diagnosis of rhinosinusitis. *Rhinology* 42(1): 15–18.
169. Vaidya AM, Chow JM, Stankiewicz JA, Young MR & Mathews HL (1997) Correlation of middle meatal and maxillary sinus cultures in acute maxillary sinusitis. *Am J Rhinol* 11(2): 139–143.
170. Kaiser L, Morabia A, Stalder H, Ricchetti A, Auckenthaler R, Terrier F *et al.* (2001) Role of nasopharyngeal culture in antibiotic prescription for patients with common cold or acute sinusitis. *Eur J Clin Microbiol Infect Dis* 20(7): 445–451.
171. Zenni MK, Cheatham SH, Thompson JM, Reed GW, Batson AB, Palmer PS *et al.* (1995) *Streptococcus pneumoniae* colonization in the young child: association with otitis media and resistance to penicillin. *J Pediatr* 127(4): 533–537.
172. Burr ML, Gray SJ & Howells CH (1982) A survey of nasal *Streptococcus pneumoniae* in children. *J Hyg (Lond)* 88(3): 425–431.
173. Faden H, Waz MJ, Bernstein JM, Brodsky L, Stanievich J & Ogra PL (1991) Nasopharyngeal flora in the first three years of life in normal and otitis-prone children. *Ann Otol Rhinol Laryngol* 100(8): 612–615.
174. Hable KA, Washington JA & Herrmann EC Jr (1971) Bacterial and viral throat flora. Comparison of findings in children with acute upper respiratory tract disease and in healthy controls during winter. *Clin Pediatr (Phila)* 10(4): 199–203.
175. Savolainen S, Jousimies-Somer H, Karjalainen J & Ylikoski J (1997) Do simple laboratory tests help in etiologic diagnosis in acute maxillary sinusitis? *Acta Otolaryngol Suppl* 529: 144–147.
176. Hansen JG, Schmidt H, Rosborg J & Lund E (1995) Predicting acute maxillary sinusitis in a general practice population. *BMJ* 311: 233–236.
177. Lindbaek M, Hjortdahl P & Johnsen UL (1996) Use of symptoms, signs, and blood tests to diagnose acute sinus infections in primary care: comparison with computed tomography. *Fam Med* 28(3): 183–188.
178. Blomgren K, Alho OP, Ertama L, Huovinen P, Korppi M, Mäkelä M *et al.* (2005) Acute sinusitis: Finnish clinical practice guidelines. *Scand J Infect Dis* 37(4): 245–250.
179. Gangel EK (2002) AAP issues recommendations for the management of sinusitis in children. *American Academy of Pediatrics. Am Fam Physician* 65(6): 1216, 1219–1216, 1220.
180. Conrad DA & Jenson HB (2002) Management of acute bacterial rhinosinusitis. *Curr Opin Pediatr* 14(1): 86–90.
181. Wald ER (1992) Sinusitis in children. *N Engl J Med* 326(5): 319–323.
182. Mäkelä M & Leinonen K (1996) Diagnosis of maxillary sinusitis in Finnish primary care. Use of imaging techniques. *Scand J Prim Health Care* 14(1): 29–35.
183. Honkanen PO, Rautakorpi UM, Huovinen P, Klaukka T, Palva E, Roine R *et al.* (2002) Diagnostic tools in respiratory tract infections: use and comparison with Finnish guidelines. *Scand J Infect Dis* 34(11): 827–830.
184. Tapiainen T, Luotonen L, Kontiokari T, Renko M & Uhari M (2002) Xylitol administered only during respiratory infections failed to prevent acute otitis media. *Pediatrics* 109(2): E19.
185. Jackson GG, Dowling HF, Spiesman IG & Boand AV. (1985) Transmission of the common cold to volunteers under controlled conditions. I. The common cold as a clinical entity. *AMA Arch Intern Med* 101(2): 267–278.
186. Revonta M (1980) Ultrasound in the diagnosis of maxillary and frontal sinusitis. *Acta Otolaryngol Suppl* 370: 1–55.

187. Lönnrot M, Sjöroos M, Salminen K, Maaronen M, Hyypiä T & Hyöty H (1999) Diagnosis of enterovirus and rhinovirus infections by RT-PCR and time-resolved fluorometry with lanthanide chelate labeled probes. *J Med Virol* 59(3): 378–384.
188. Grondahl B, Puppe W, Hoppe A, Kuhne I, Weigl JA & Schmitt HJ (1999) Rapid identification of nine microorganisms causing acute respiratory tract infections by single-tube multiplex reverse transcription-PCR: feasibility study. *J Clin Microbiol* 37(1): 1–7.
189. Ukkonen P, Varis K, Jernfors M, Herva E, Jokinen J, Ruokokoski E *et al.* (2000) Treatment of acute otitis media with an antiadhesive oligosaccharide: a randomised, double-blind, placebo-controlled trial. *Lancet* 356(9239): 1398–1402.
190. Kilpi T, Herva E, Kaijalainen T, Sytjänen R & Takala AK (2001) Bacteriology of acute otitis media in a cohort of Finnish children followed for the first two years of life. *Pediatr Infect Dis J* 20(7): 654–662.
191. Miettinen O & Nurminen M (1985) Comparative analysis of two rates. *Stat Med* 4(2): 213–226.
192. Kaplan EL & Meier P (1958) Nonparametric estimation from incomplete observations. *J Am Stat Assoc* 53: 457–481.
193. Mantel N (1966) Evaluation of survival data and two new rank order statistics arising in its consideration. *Cancer Chemother Rep* 50(3): 163–170.
194. Cox DR (1972) Regression models and life-tables (with discussion). *J R Stat Soc* 34: 187–220.
195. McAlister WH, Parker BR, Kushner DC, Babcock DS, Cohen HL, Gelfand MJ *et al.* (2000) Sinusitis in the pediatric population. American College of Radiology. ACR Appropriateness Criteria. *Radiology* 215 Suppl: 811–818.
196. Sinus and Allergy Health Partnership (2000) Antimicrobial treatment guidelines for acute bacterial rhinosinusitis. *Otolaryngol Head Neck Surg* 123(1 Pt 2): 5–31.
197. Lanza DC & Kennedy DW (1997) Adult rhinosinusitis defined. *Otolaryngol Head Neck Surg* 117(3 Pt 2): S1–S7.
198. Gordts F, Abu Nasser I, Pierard D, Meyvisch P & Clement PA (1999) Microbiology of the middle meatus in children requiring adenotonsillectomy. *J Laryngol Otol* 113(1): 24–27.
199. Hadley JA & Schaefer SD (1997) Clinical evaluation of rhinosinusitis; History and physical examination. *Otolaryngol Head Neck Surg* 117(3 Pt 2): S8–11.
200. Kaiser L, Lew D, Hirschel B, Auckenthaler R, Morabia A, Heald A *et al.* (1996) Effects of antibiotic treatment in the subset of common-cold patients who have bacteria in nasopharyngeal secretions. *Lancet* 347(9014): 1507–1510.